The Vision for Change: 2D, 3D, and 4D Imaging in Dentistry

148th SCDA Annual Session
April 27-30, 2017
Charleston Marriott | Charleston, SC




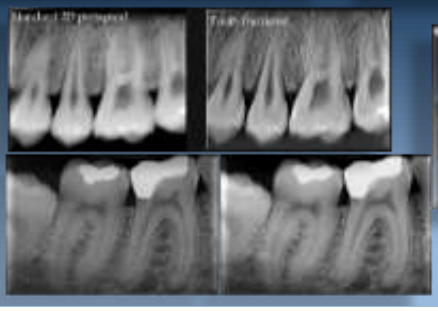
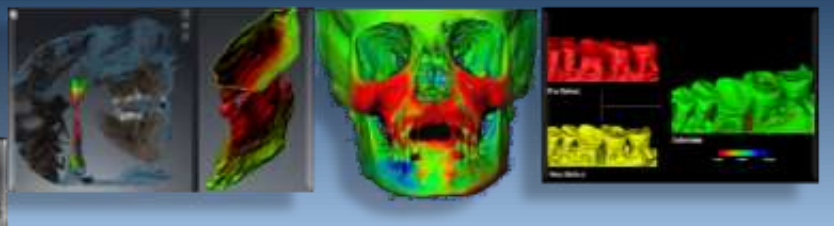

Don Tyndall, DDS, MSPH, PhD

Today's Agenda

- Brief overview of 2D imaging advances: Intraoral and panoramic
- Cone beam CT: technology, radiation risks, and legal responsibilities
- Cone beam CT: Clinical applications and integration into digital dentistry
- Segmentation and 4D imaging
- Intraoral digital tomosynthesis: The "new" 3D current technology and future promise
- Q & A

The Stone Age didn't end because they ran out of stones

It ended because they discovered new technology that worked better

Brief overview of intraoral radiography advances

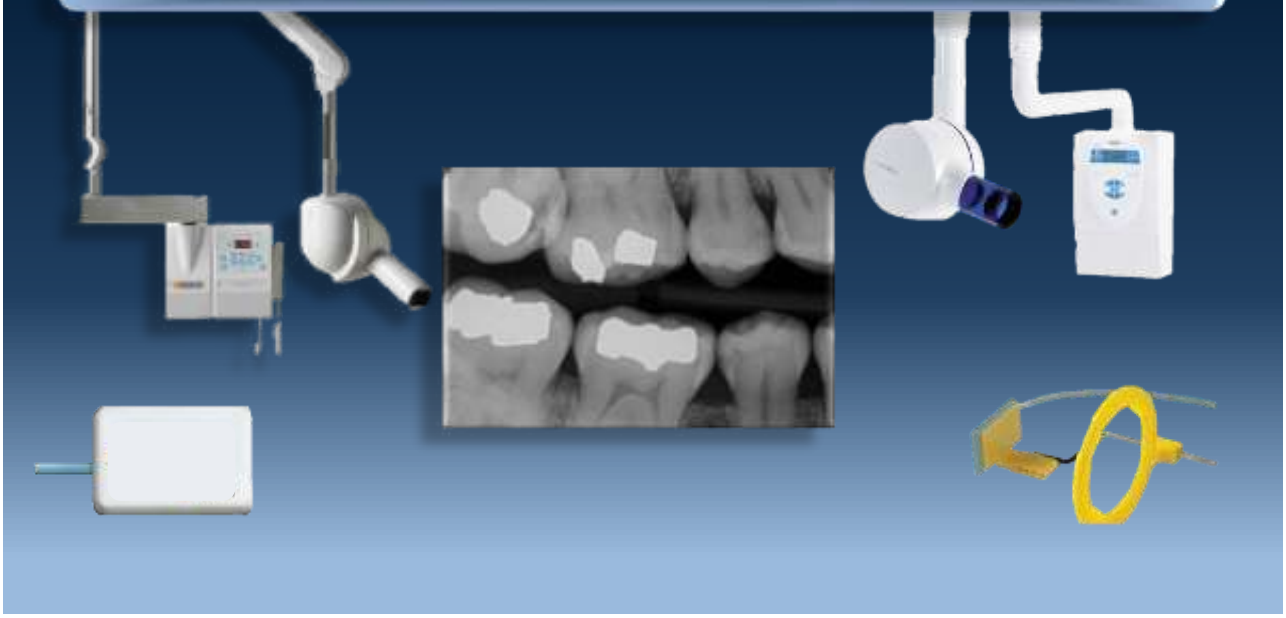

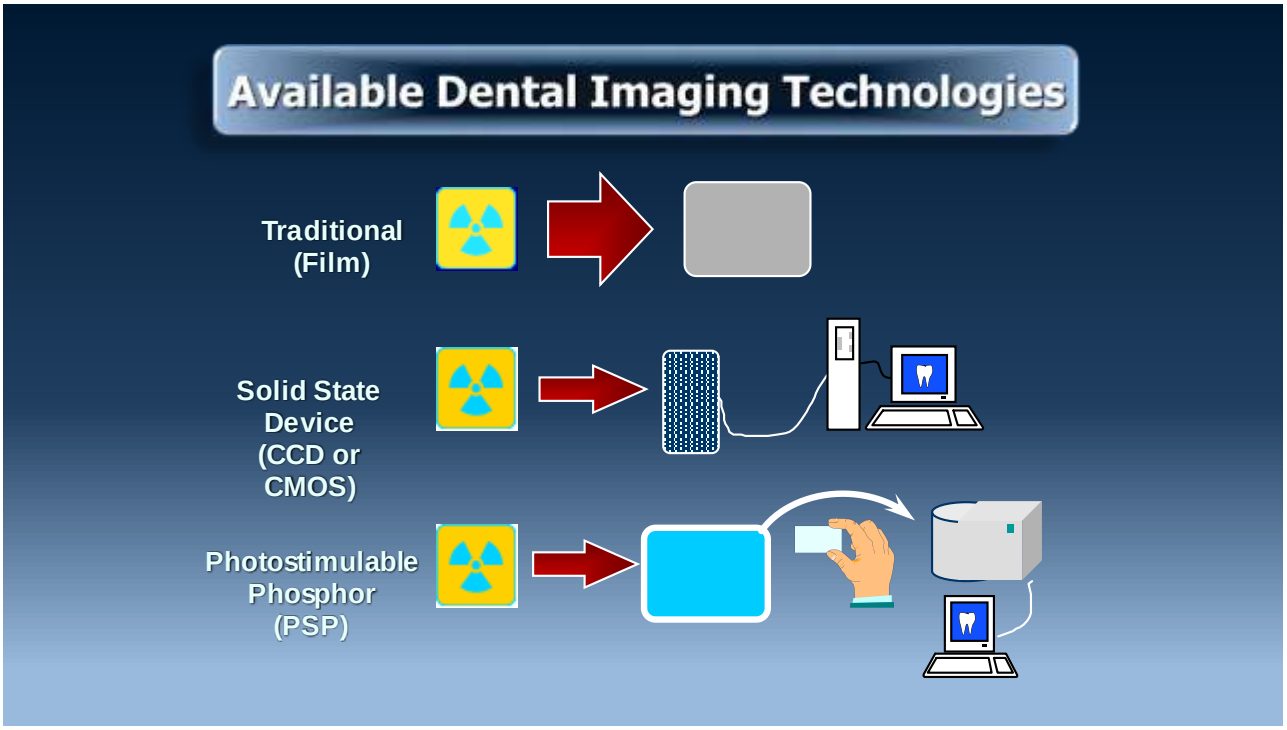
Available Dental Imaging Technologies
Traditional (Film)
Solid State Device (CCD or CMOS)
Photostimulable Phosphor (PSP)

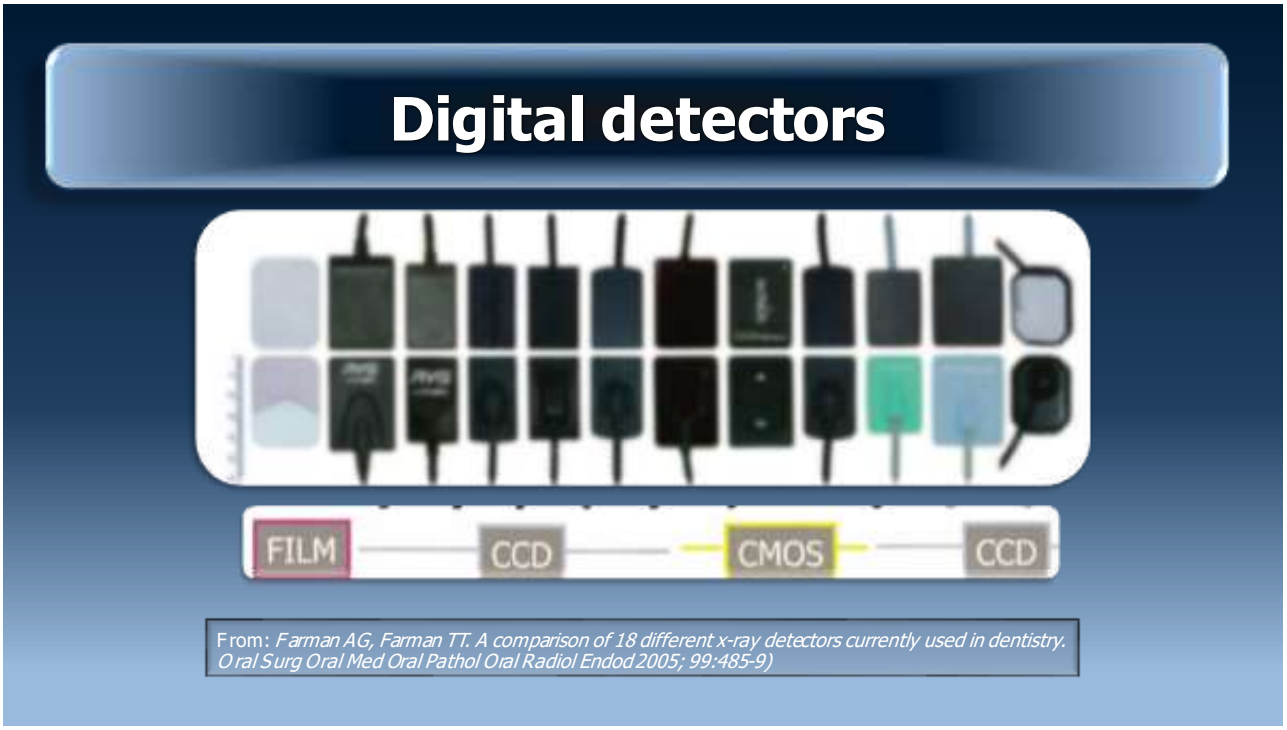
Digital detectors
FILM
CCD
CMOS
CCD
From: Farman AG, Farman TT. A comparison of 18 different x-ray detectors currently used in dentistry. Oral Surg Oral Med Oral Pathol Oral Radiol Endod 2005; 99:485-9)

How a digital detector works

- Scintillator material: converts X rays to light
- Fiber optic plate: guides light to the sensor
- CMOS sensor: light converted to an analogue signal
- Electronics: analogue signal is converted into a digital signal
- Signal is displayed on a monitor

Cable Issues…….. Not talking about cable TV

- **Single largest problem with sensors**
- **Solutions:**
  - **Replaceable wire**
  - **45 degree angle**
  - **Kevlar wrapped**
  - **Reinforced connect points**
  - **Strain relief cable**
  - **Swivel (novel at least)**

Photostimulable Phosphor (PSP)

- 100% re-usable
- Same size as film
- Somewhat flexible
- Thin
- No wires

PSP scanner

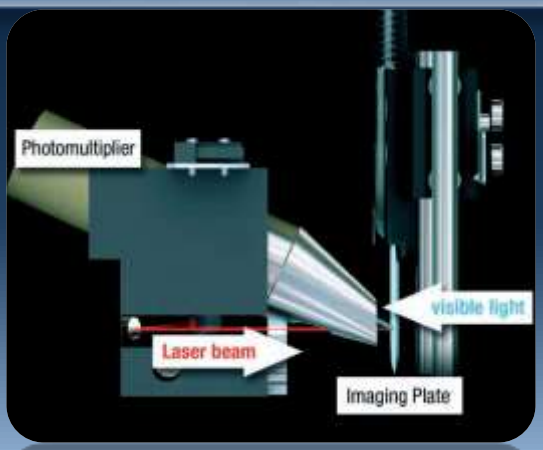

Soredex OpTime

Diagnostic Accuracy

Direct Digital = PSP = Film

- Over 100 papers have demonstrated that there are no differences in diagnostic efficacy for any of the intraoral systems in use today
- This includes almost all forms of image processing as well
- This leads many to believe that IMAGING GEOMETRY may be the problem

No Processing Problems with Digital Imaging

What About Radiation Risks for Intraoral Radiography?



Radiation Dose for Intraoral Imaging

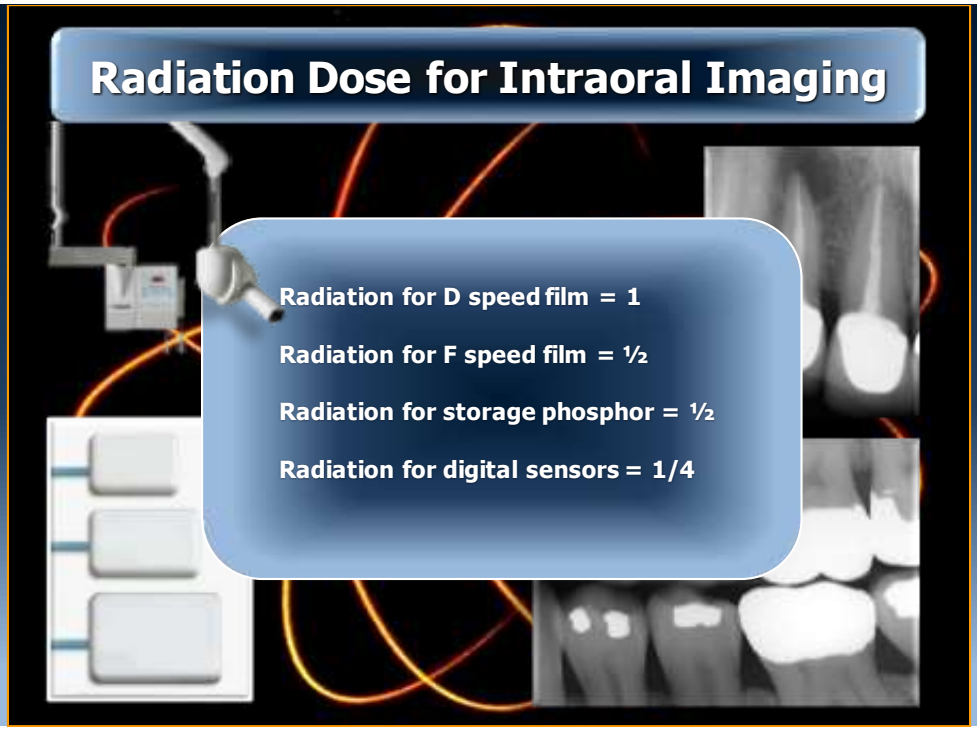

Radiation for D speed film = 1

Radiation for F speed film = ½

Radiation for storage phosphor = ½

Radiation for digital sensors = 1/4

Digital Image Processing

Useful tools

- Contrast, Brightness
- Zoom
- Rulers

Sometimes useful

- Special filters
- Edge enhancement

Occasionally useful

- Inversion
- Color conversion (pseudo-color)
- Embossing

Special filters: "Caries detection"

Caries can be enhanced but this tool can introduce artifacts so use it only in specifically small regions.

Special filters: edge enhancements or sharpening

Not enhanced

Enhanced: Careful not to overdo it
False positives can be created

Digital images can be enhanced by software increases the potential for greater patient understanding.
Film cannot be changed. What comes out of the processor is what you get.

Task Specific Filters

- Sharpening
- General
- Endodontic
- Periodontic
- Restorative

Note: The effectiveness of some of these has yet to be scientifically demonstrated

General Dentistry

Endodontic

Periodontic

Restorative

Image Enhancement Research

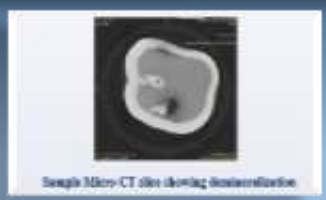

- Selected filters had no effect on the diagnostic efficacy for caries detection or for cavitation detection or for dentin penetration….more research needed
- Dual observers performed the same as single observers

Panoramic Imaging Advances: Basically Three

- Panoramic Bitewings
  - Great idea but not yet ready to replace intraoral imaging……..getting closer
- Panoramic Tomosynthesis
  - Choose among several image layers
  - Adjustable to correct for some positioning errors
  - Some units take 4200 pictures and stich together the sharpest layers
- Direct X ray detectors- no x-ray to light conversion

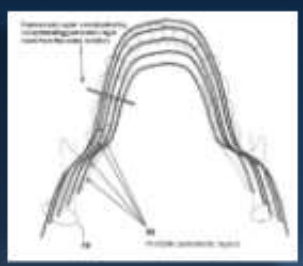

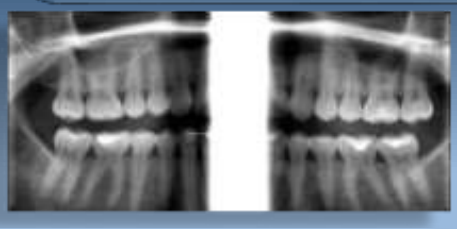

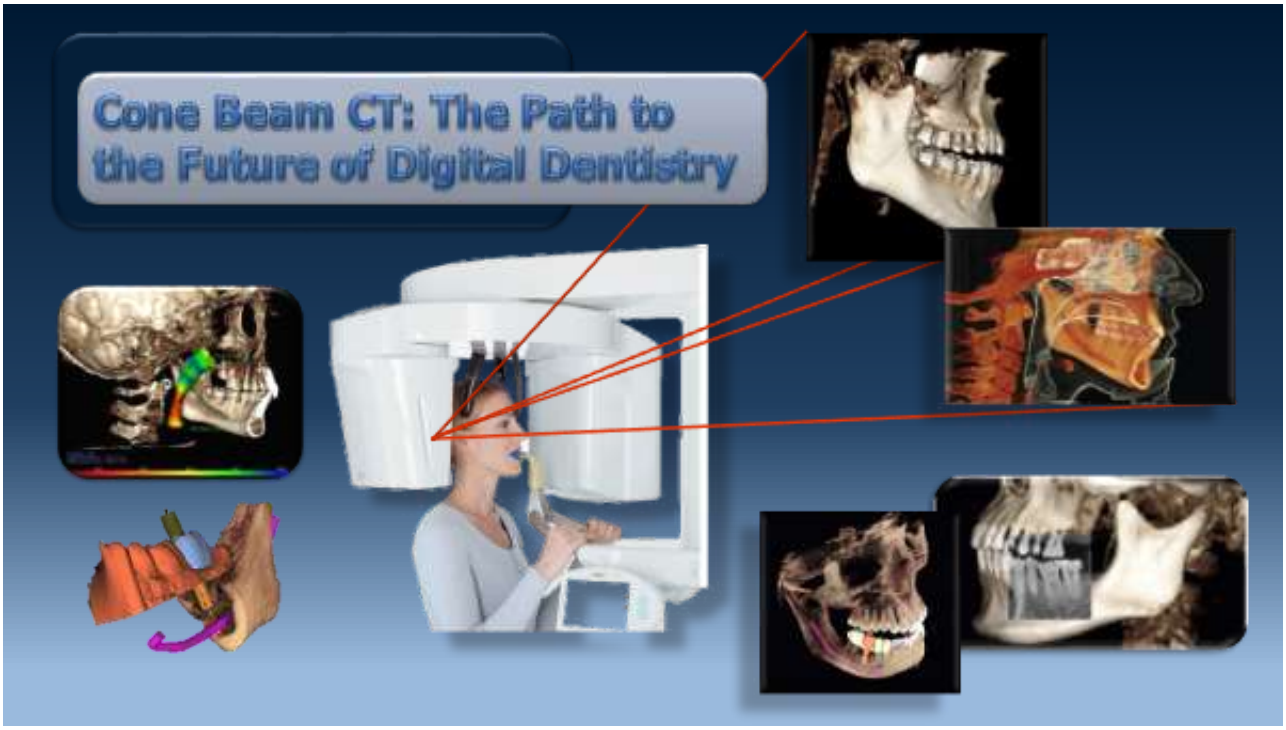

Five Questions to Answer

- What is 3-D cone beam computed tomography (CBCT) and how does it work?
- What do you need to consider when purchasing a CBCT system?
- What radiation doses and risks are associated with CBCT?
- What legal responsibilities come with CBCT?
- What are the current clinical applications of CBCT?

Early Dental Radiology

Basically the same as it is today….in terms of geometry


The Primary Problem with Two Dimensional Imaging:
It is the End of the Road for Improvements in Diagnosis and Treatment Planning

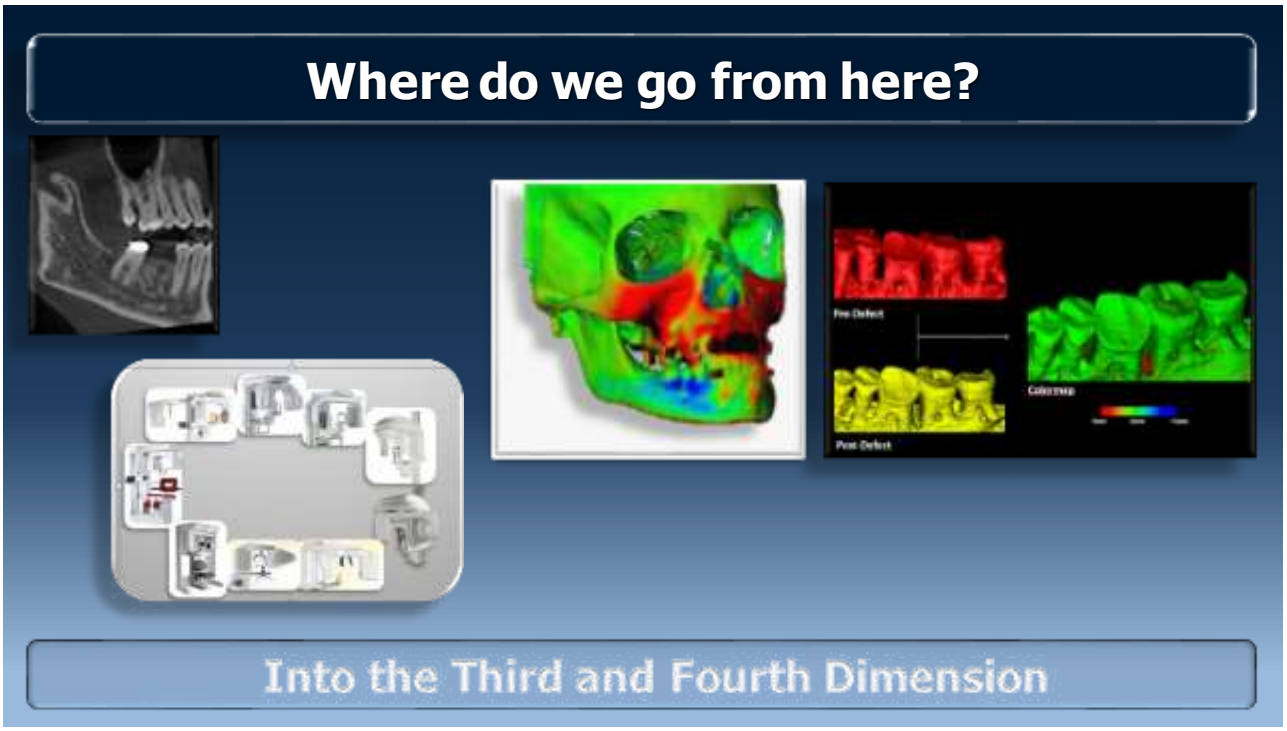
Where do we go from here?
Into the Third and Fourth Dimension

The First CBCT System: The Dynamic Spatial Reconstructor

Early 1980s

3-D Cone Beam CT Imaging: Three Advantages

- Foundation for digital dentistry
- Patient education

- Diagnosis and treatment planning

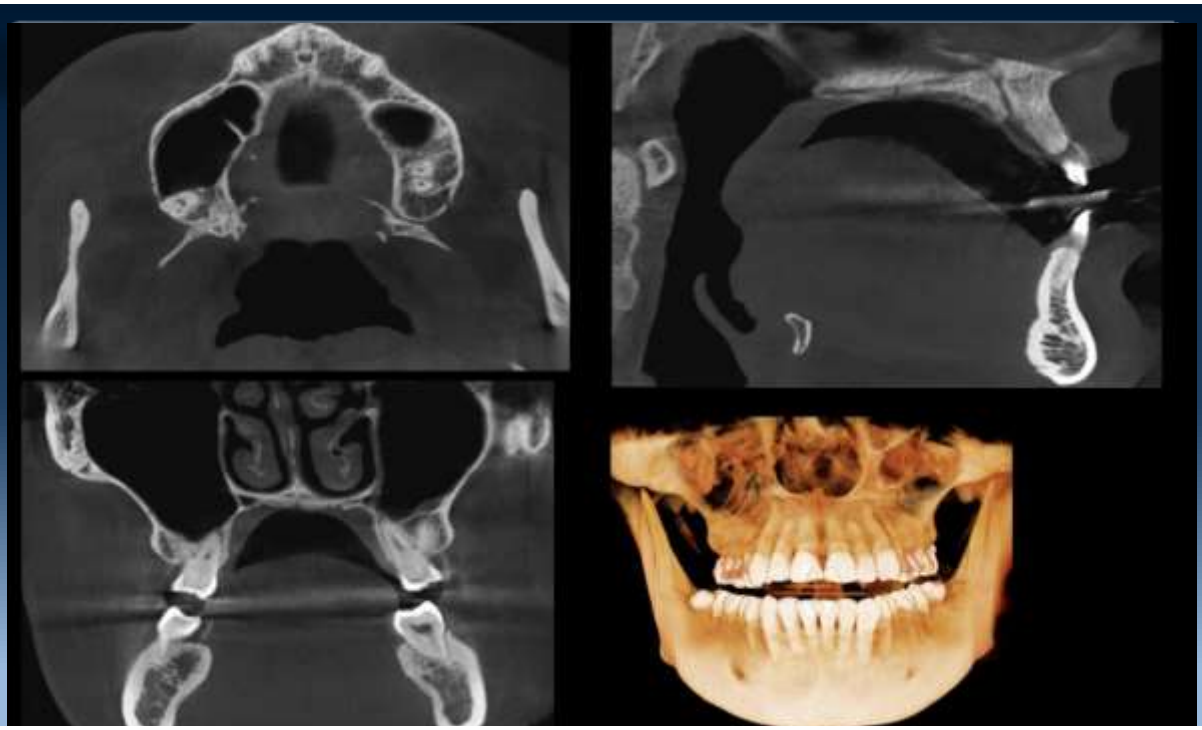

Image Acquisition:
A series of *skull projections (a video)*

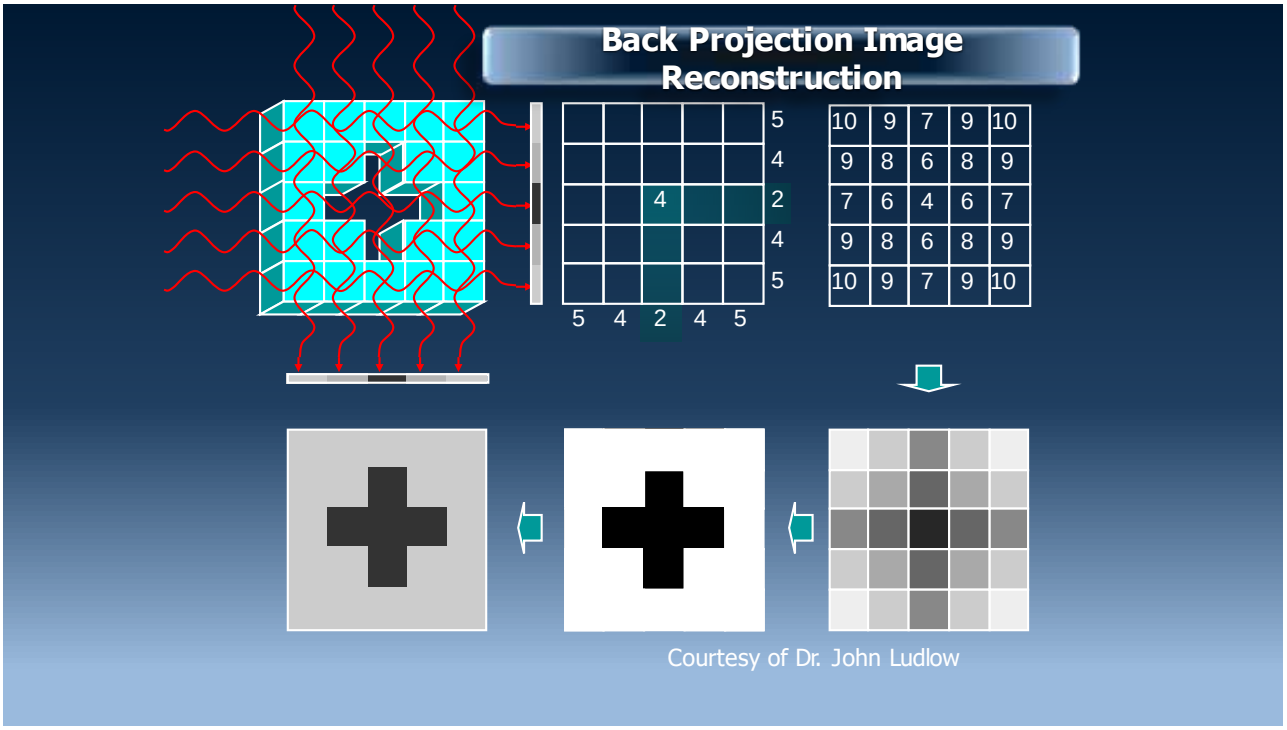
Back Projection Image Reconstruction
5
4
2
4
5
5 4 2 4 5
10 9 7 9 10
9 8 6 8 9
7 6 4 6 7
9 8 6 8 9
10 9 7 9 10
Courtesy of Dr. John Ludlow


CT Image Reconstruction

CT Image Reconstruction



CT Development and the Beatles

EMI

Electrical and Musical Industries Records

How is CBCT different from conventional medical CT?

CONVENTIONAL CT
- Fan-beam
- Multiple revolutions
- Unlimited scan volume
- Little scatter; soft tissue detail
- Higher costs
- Higher Dose

CONE BEAM CT
- Cone-beam
- One revolution
- Limited scan volume
- Lots of scatter; hard tissue only
- Lower Costs
- Lower Dose

Representative Fields of View

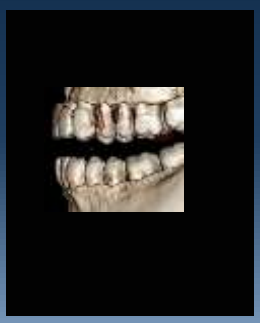

Fields of View

15.5 by 15.5 cm

11 x 10 cm

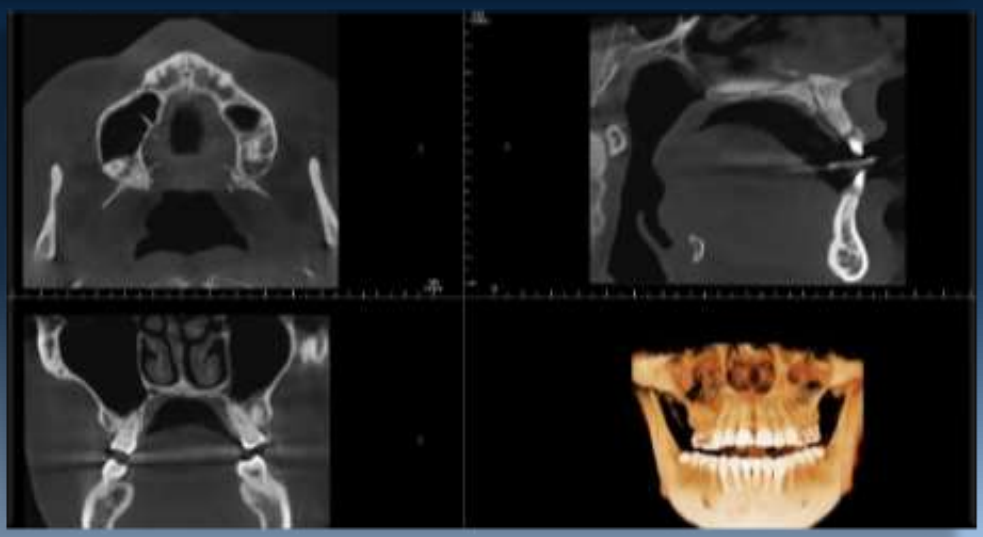

8x8 cm Field of View

5x5 cm Field of View

What About Radiation Risks?



CBCT Effective Doses (2007 ICRP) Adults

NOTE: Keep in mind that these are always changing and are dependent on multiple factors

These data were based on 167 adult exposure combinations

- Large FOV CBCT scans for all protocols
  46 - 1073 µSv
  - **For standard protocols the mean is 212 µSv**
- Medium FOV CBCT scans
  9 - 560 µSv
  - **For standard protocols the mean is 177 µSv**
- Small FOV CBCT scans
  5 - 652 µSv
  - **For standard protocols the mean is 84 µSv**

Ludlow JB, Timothy R, Walker C, Hunter R, Benavides E, Samuelson DB,et al.
Effective dose of dental CBCT—a meta analysis of published data and additional data for nine CBCT units. Dentomaxillofac Radiol 2015; 44: 20140197.

Stochastic vs Deterministic Effects

Stochastic effects

- **Effects where the *risk* is *proportional* to the dose**
- **Implies that there is no threshold**
- **e.g. cancer, mutations (genetic effects)**
- **Severity of the effect is independent of the dose**

Deterministic effects

- **Effects where the *severity* is *proportional* to the dose**
- **Implies a threshold**
- **e.g. sunburn, *in-utero* birth defects, cataracts, radiation burns**
- **Dose threshold for birth defects 100-250 mSv (note effective dose for dental radiographs is in microsieverts**

Reference from the Health Physics Society

- Most diagnostic procedures expose the embryo to less than 50 mSv.[1]
- This level of radiation exposure will not increase reproductive risks (either birth defects or miscarriage).
- According to published information, the reported dose of radiation to result in an increased incidence of birth defects or miscarriage is above 200 mSv.
- Note in dentistry we measure dose in ***microsieverts***

-Robert Brent, MD, PhD

https://hps.org/hpspublications/articles/pregnancyandradiationexposureinfosheet.html

Radiological Responsibility

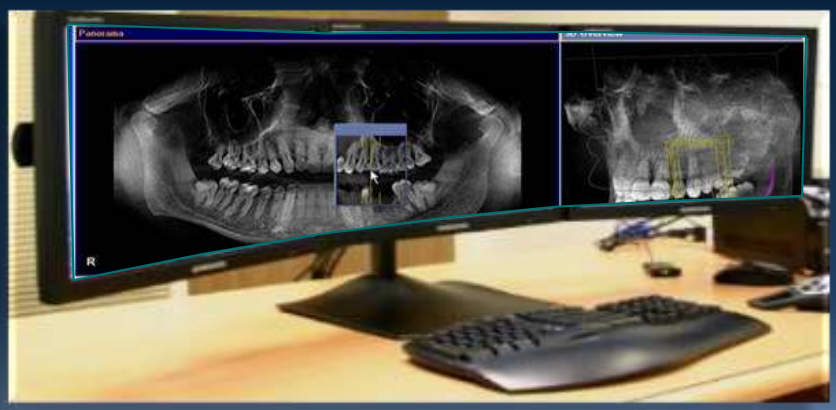

Who is responsible for reading CBCT data?

Radiological Responsibility

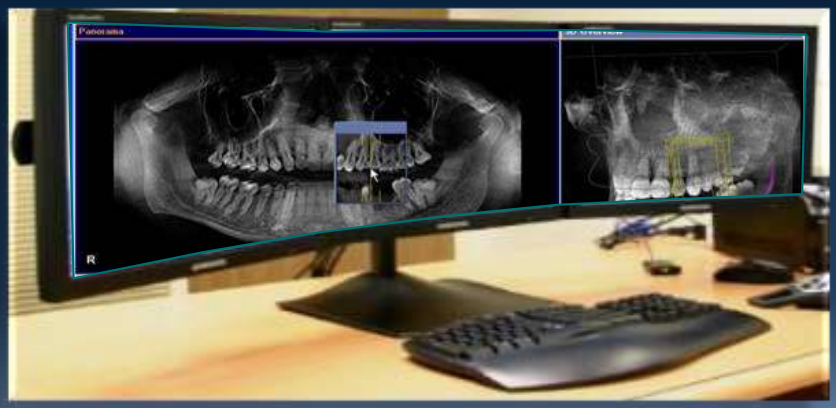

Someone is

Ethical and Legal Responsibilities

- The entire scanned volume should be examined
- Recognition of abnormal and appropriate referral
- Training is offered by most manufacturers
- There are oral and maxillofacial radiologists that can help



Radiographic Signs: these do not change much for CBCT Imaging

1. Radiographic density
2. Margin characteristics
3. Shape
4. Location and distribution
5. Size
6. Internal architecture
7. Effect on surrounding tissue

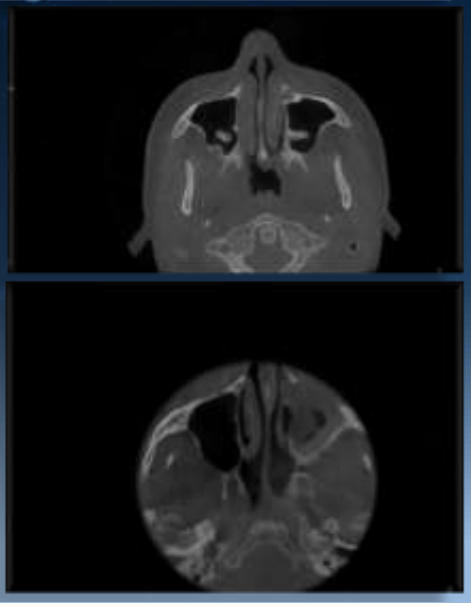

Current Applications for Cone Beam CT Imaging

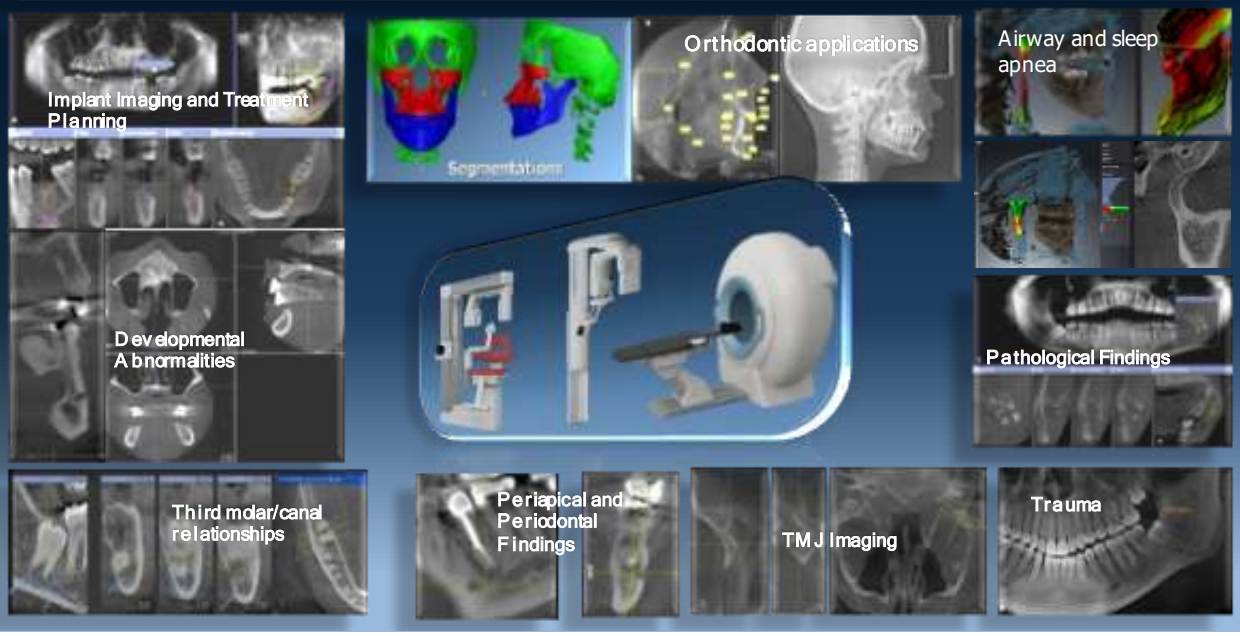

3D vs 2D: General Principle.

1. 2D underestimates bone loss
2. 2D overestimates bone gain
3. 3D is free of angulation artifacts


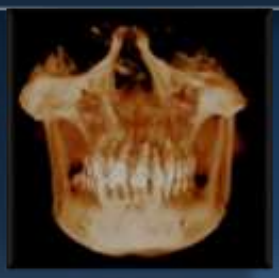



1

CBCT for Implant Site Assessment: A major reason for CBCT purchases



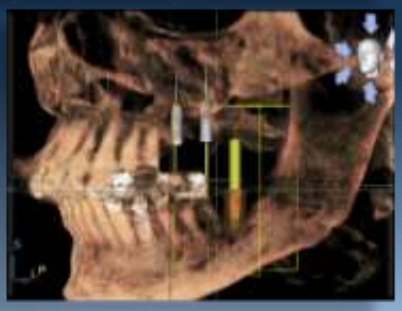

A case performed without 3D treatment planning

- 2D periapical radiograph seems to indicate that the implant was successfully placed
- It did osseointegrate (about 90% do)
- .....but

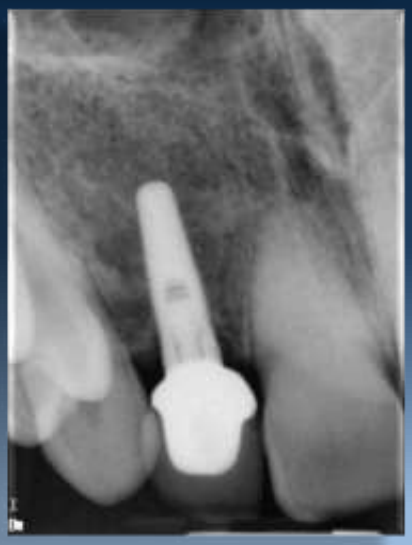

All is not as it seems....

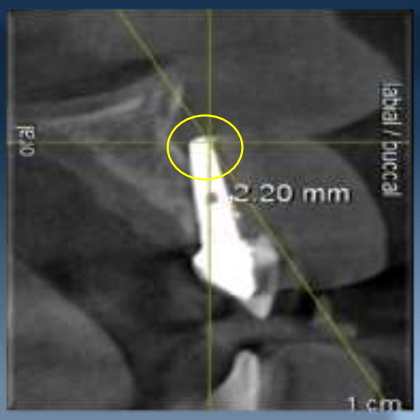

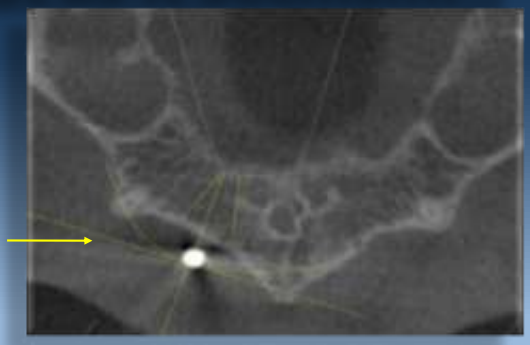

Furcation lesion induced by failed implant

Immediate post-op

1 month post-op

6 weeks post-op

Furcation lesion induced by failed implant

Implant placement without a CBCT volume

Don't try this at home….or without a CBCT scan

Recommendations for Implant Imaging

Position statement of the American Academy of Oral and Maxillofacial Radiology on selection criteria for the use of radiology in dental implantology with emphasis on cone beam computed tomography

Donald A. Tyndall, DDS, MSPH, PhD,[a] Jeffery B. Price, DDS, MS,[b] Sotirios Tetradis, DDS, PhD,[c] Scott D. Ganz, DMD,[d] Charles Hildebolt, DDS, PhD,[e] and William C. Scarfe, BDS, MS[f]

A Position Paper Subcommittee of the American Academy of Oral and Maxillofacial Radiology (AAOMR) reviewed the literature since the original position statement on selection criteria for radiology in dental implantology, published in 2000. All current planar modalities, including intraoral, panoramic, and cephalometric, as well as cone beam computed tomography (CBCT) are discussed, along with radiation dosimetry and anatomy considerations. We provide research-based, consensus-derived clinical guidance for practitioners on the appropriate use of specific imaging modalities in dental implant treatment planning. Specifically, the AAOMR recommends that cross-sectional imaging be used for the assessment of all dental implant sites and that CBCT is the imaging method of choice for gaining this information. This document will be periodically revised to reflect new evidence. (Oral Surg Oral Med Oral Pathol Oral Radiol 2012;113:817-826)

Specifically, the AAOMR recommends <u>that cross-sectional imaging be used for the assessment of all dental implant sites and that CBCT is the imaging method of choice for gaining this information.</u>


Implants and Surgical Guides
Surgical Guide
with CAD/CAM integration
One of the best reasons for a CBCT system

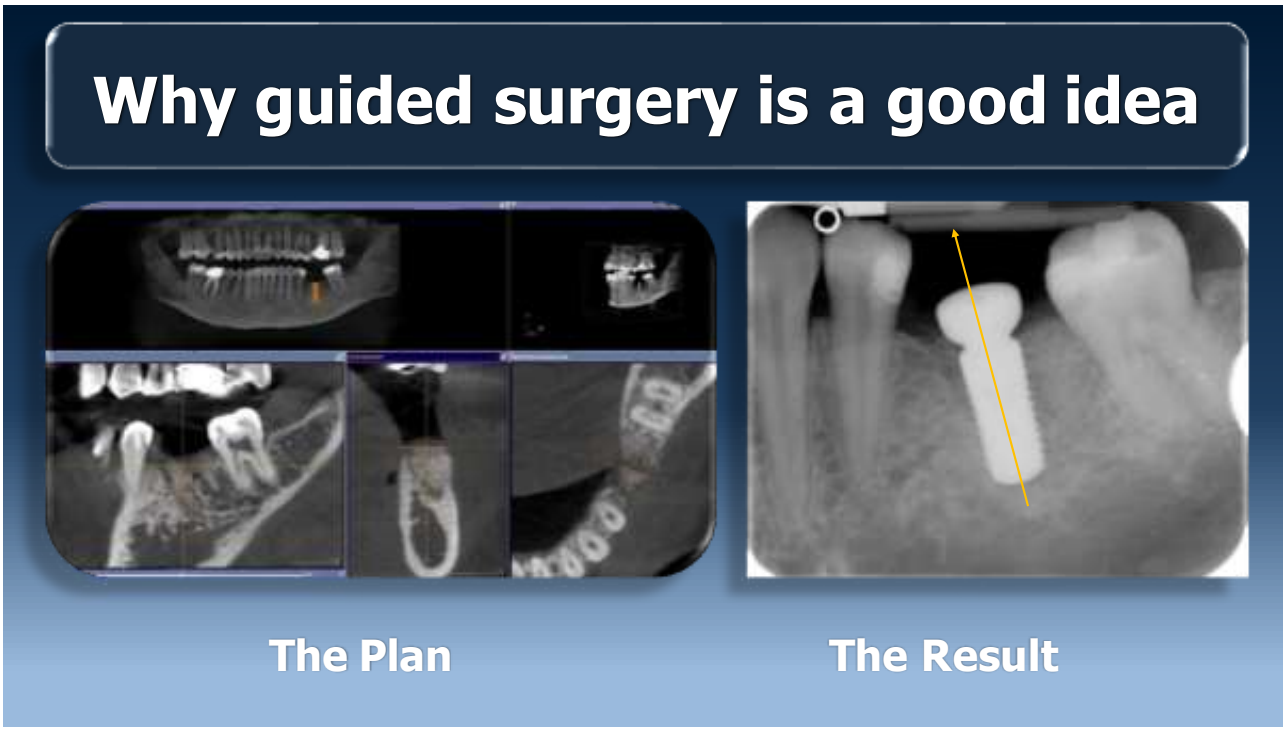
Why guided surgery is a good idea
The Plan
The Result

2.

Developmental Abnormalities

Impacted teeth

An unusual dental anomaly

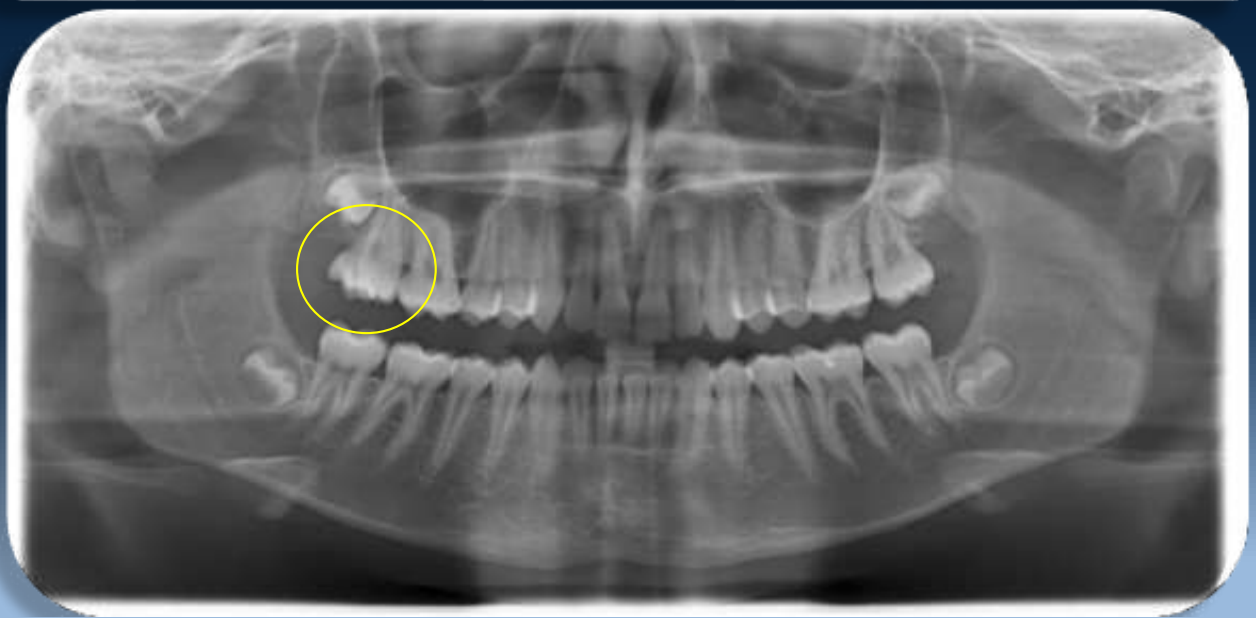

A supernumerary attached to the second molar

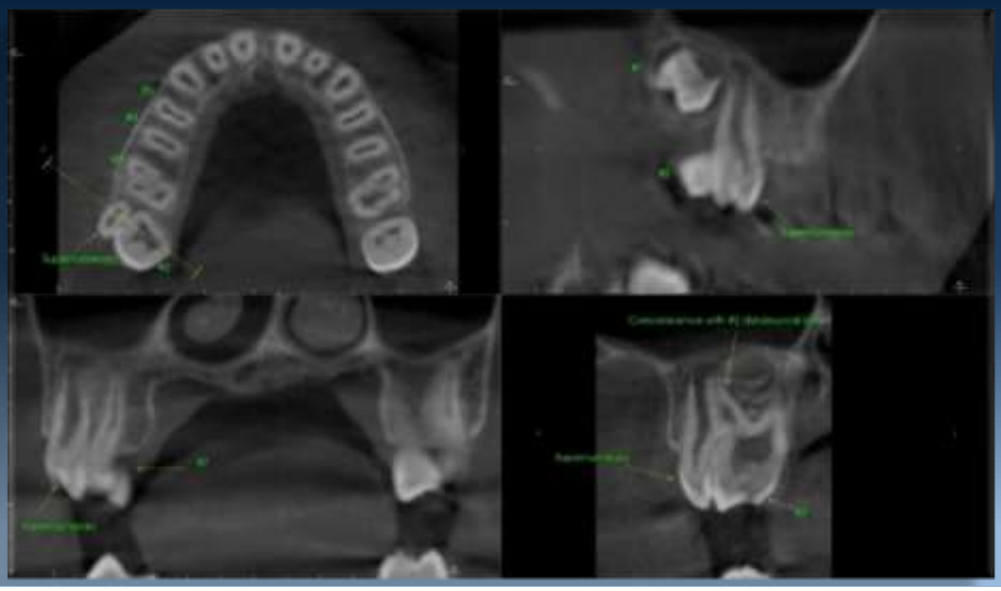

Lateral incisor did not respond to endodontic therapy

A secondary root was found

Identification of ankylosed teeth

Possible paramolars adjacent to the maxillary third molars?

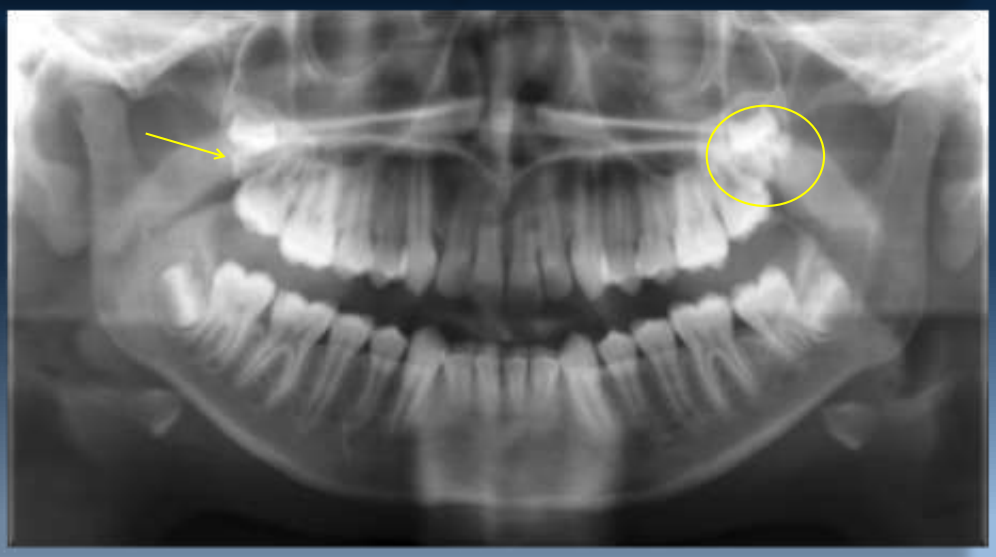

Paramolar location revealed clearly on CBCT

Two paramolars on the left side revealed clearly on CBCT

Unilateral radiolucency

Cyst or tumor…….or something else?

Answer: Stafne Bone Defect

3.

Third Molar and Canal Position

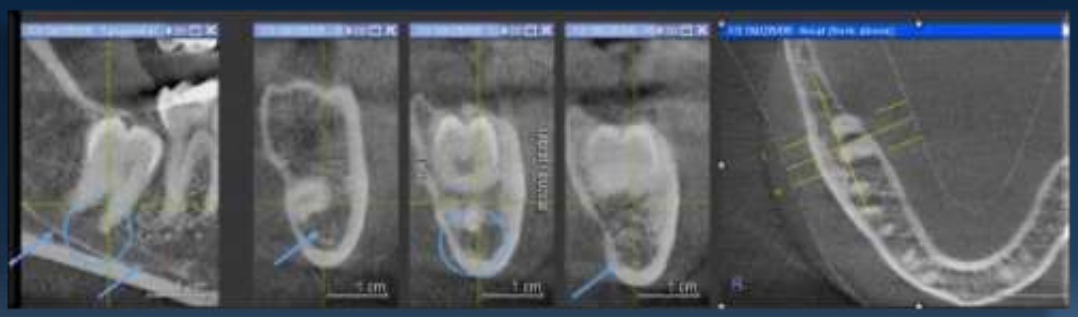

In these views the relationship of the mandibular canal and impacted third molar is revealed.

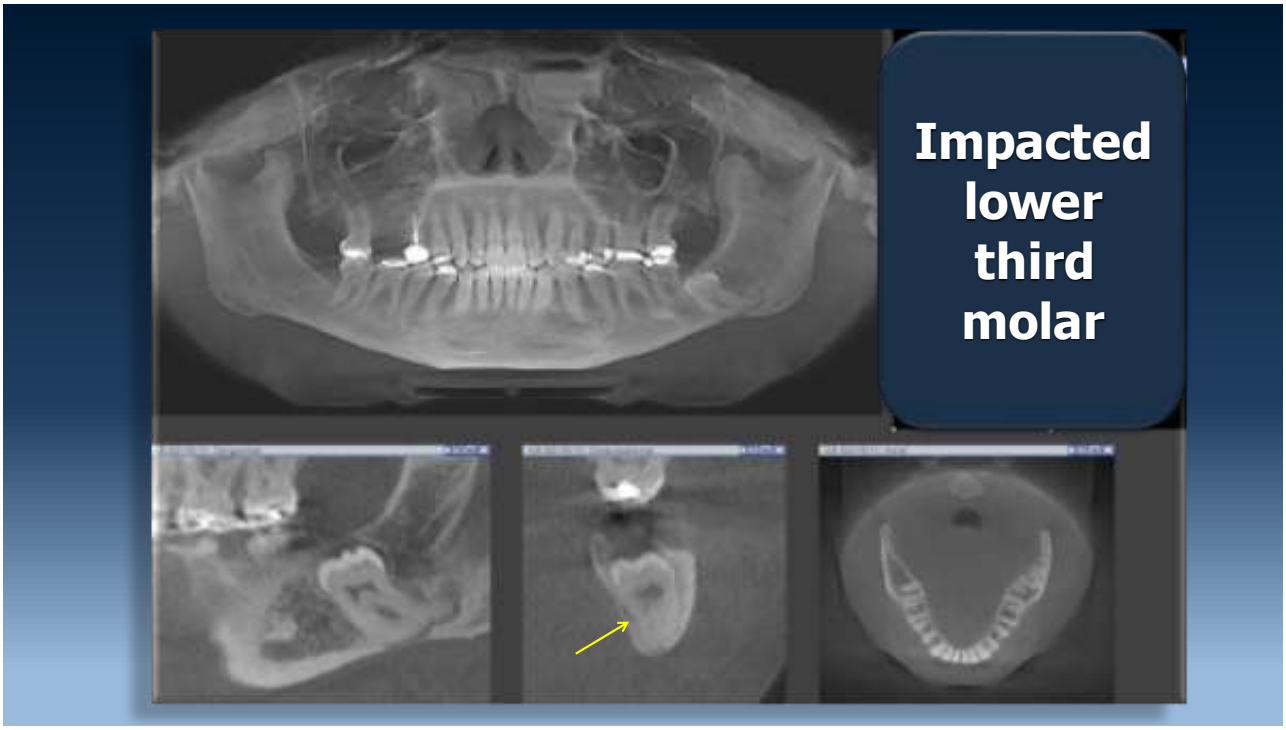

4.

Endodontic and periodontal applications

Root Fracture Case: Why did the root canal treatment fail?

Root fracture case

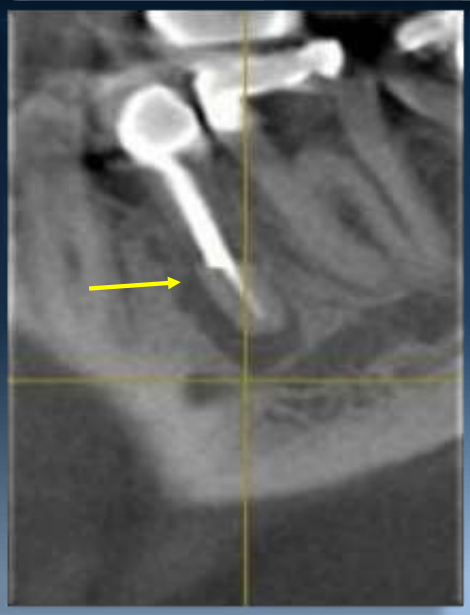

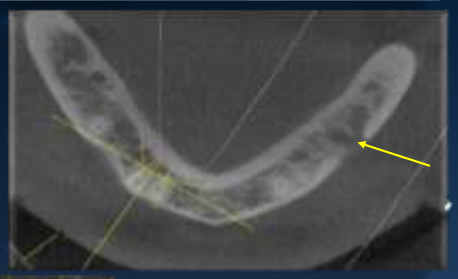

The radiolucency extends to the level of the root fracture. This was not seen in the pa view

Apical periodontitis and cardiovascular disease

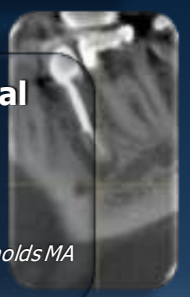

- Recent research has demonstrated a connection between apical periodontitis and a greater risk for cardiovascular disease

  "Apical periodontitis and incident cardiovascular events in the Baltimore Longitudinal Study of Ageing"

  Gomes MS, Hugo FN, Hilgert JB, Sant'Ana Filho M, Padilha DMP, Simonsick ED, Ferrucci L, Reynolds MA
  International Journal of Endodontics: 2016 49 (*4) 334-342*

Size of apical lesion at the time of RCT and success rate

Recent research has also shown that the larger the lesion at the time of RCT the greater the risk for failure of the treatment

Endodontic applications: Persistent sensitivity on #3

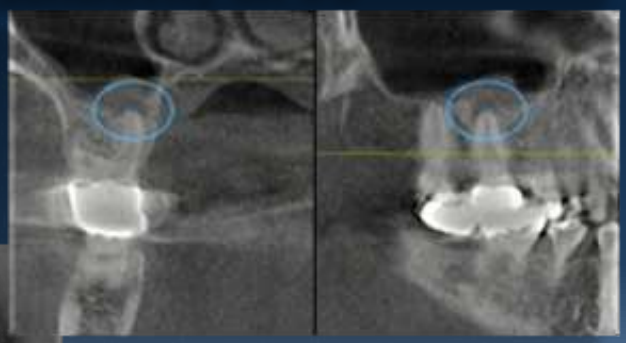

Non corticated lesion between #8, 9

First impression was nasopalatine duct cyst…….CBCT revealed something else

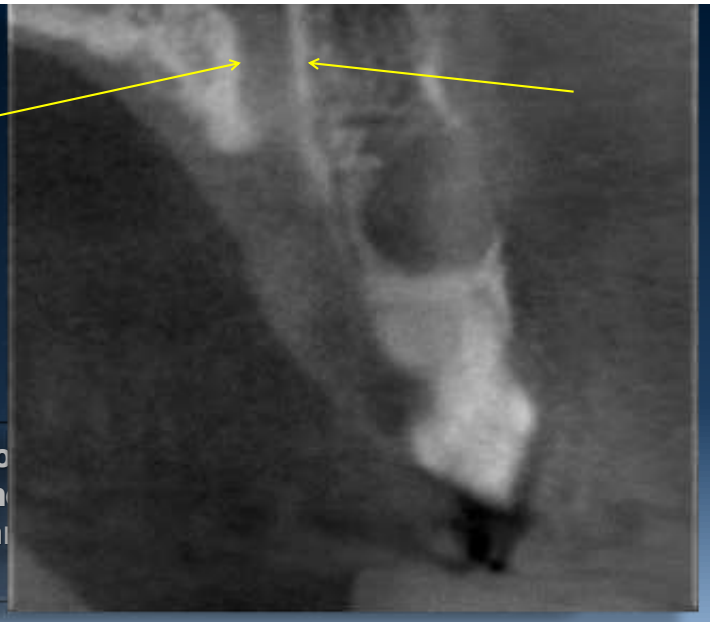

No
Th
ca

It may be a possible fracture or an odontogenic cyst or tumor

Corticated

lesion centered

over #9, 9

Periapical lesion? Note that the periodontal ligament space is intact

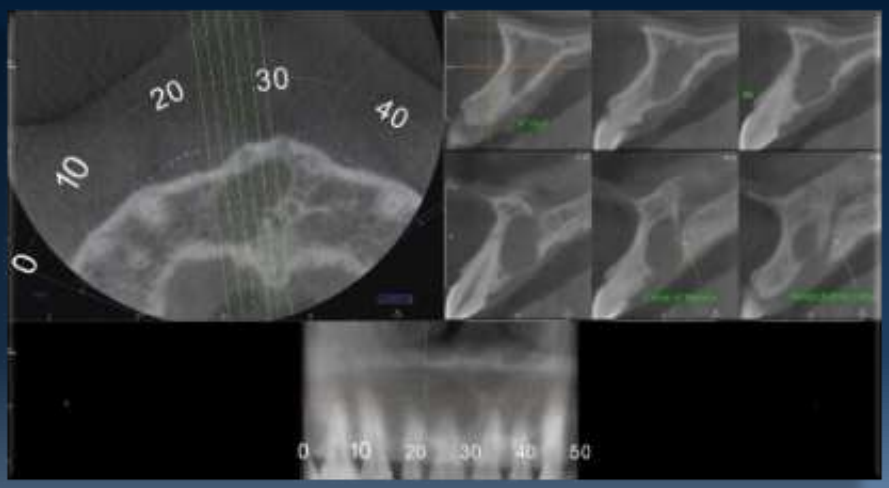

Corticated lesion centered over #8 revealed to be a Keratocystic Odontogenic Tumor (aka "OKC")

First impression was periapical lesion…….CBCT revealed something else
But not a nasopalatine duct cyst…no connection to the canal

Patient with mild discomfort

The periapical radiograph revealed very little bone loss

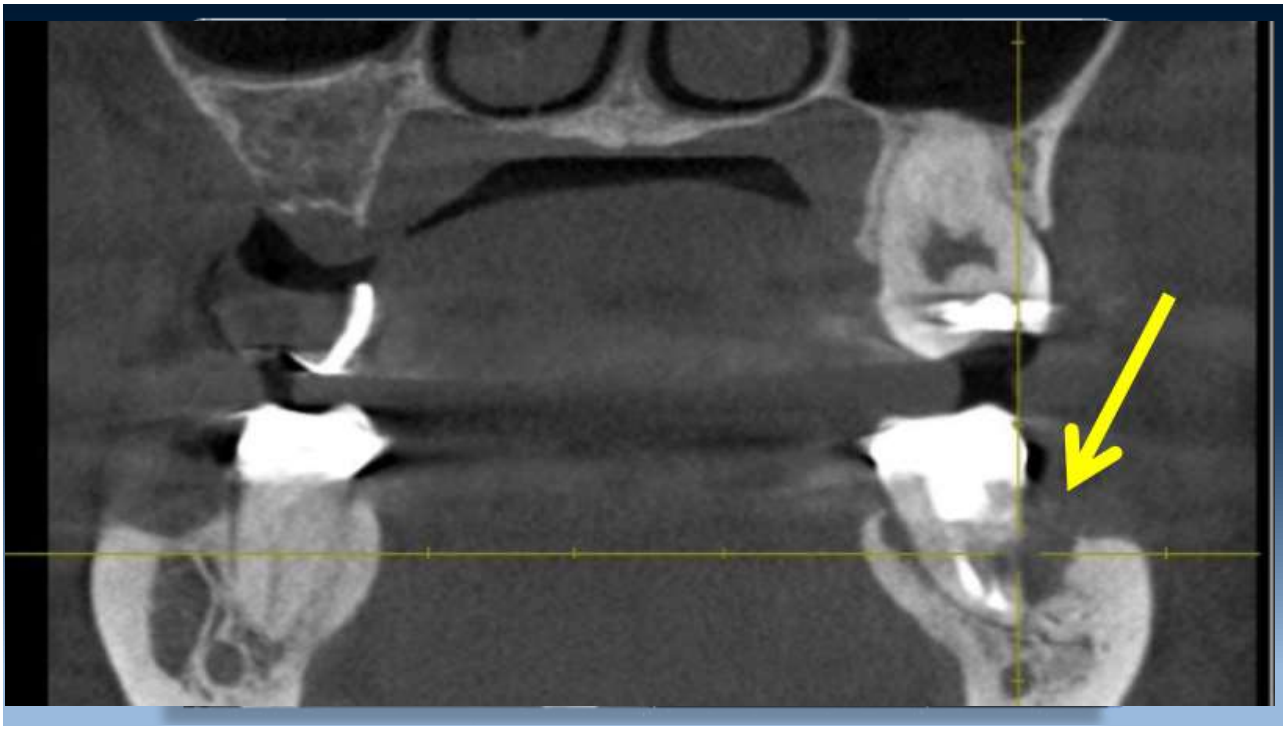

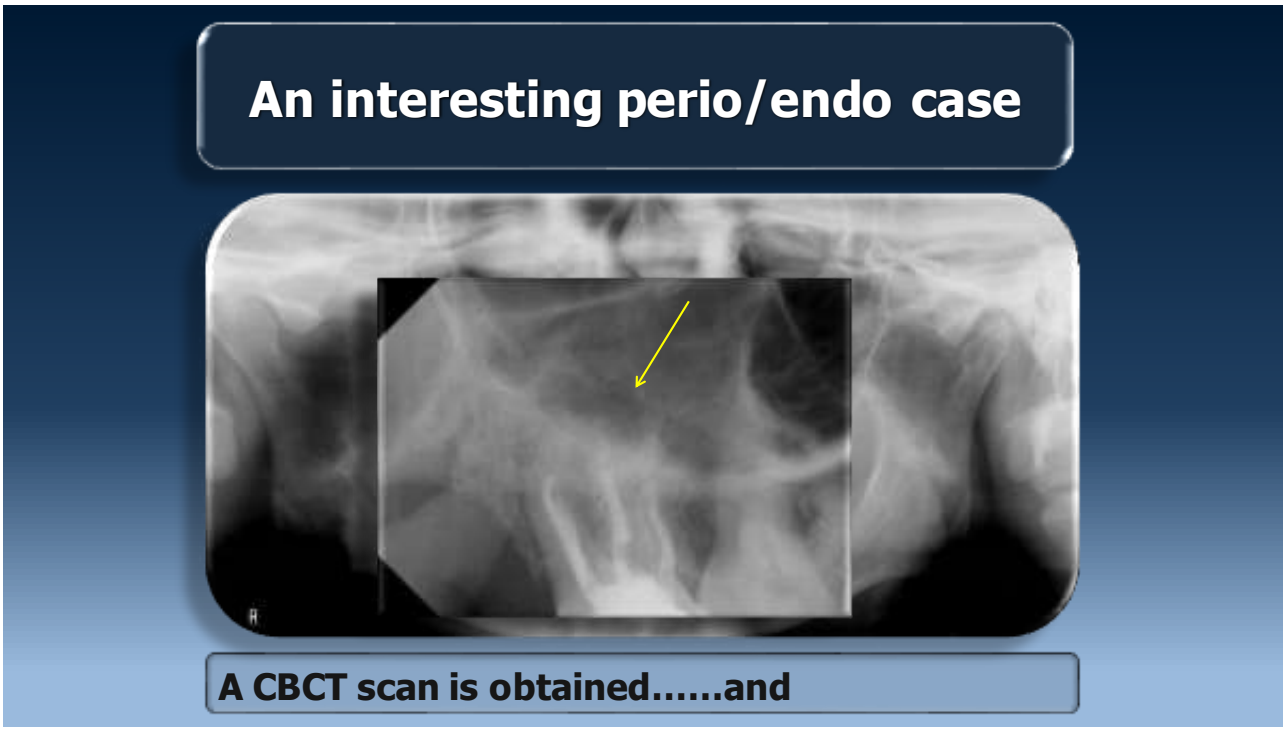
An interesting perio/endo case
A CBCT scan is obtained……and

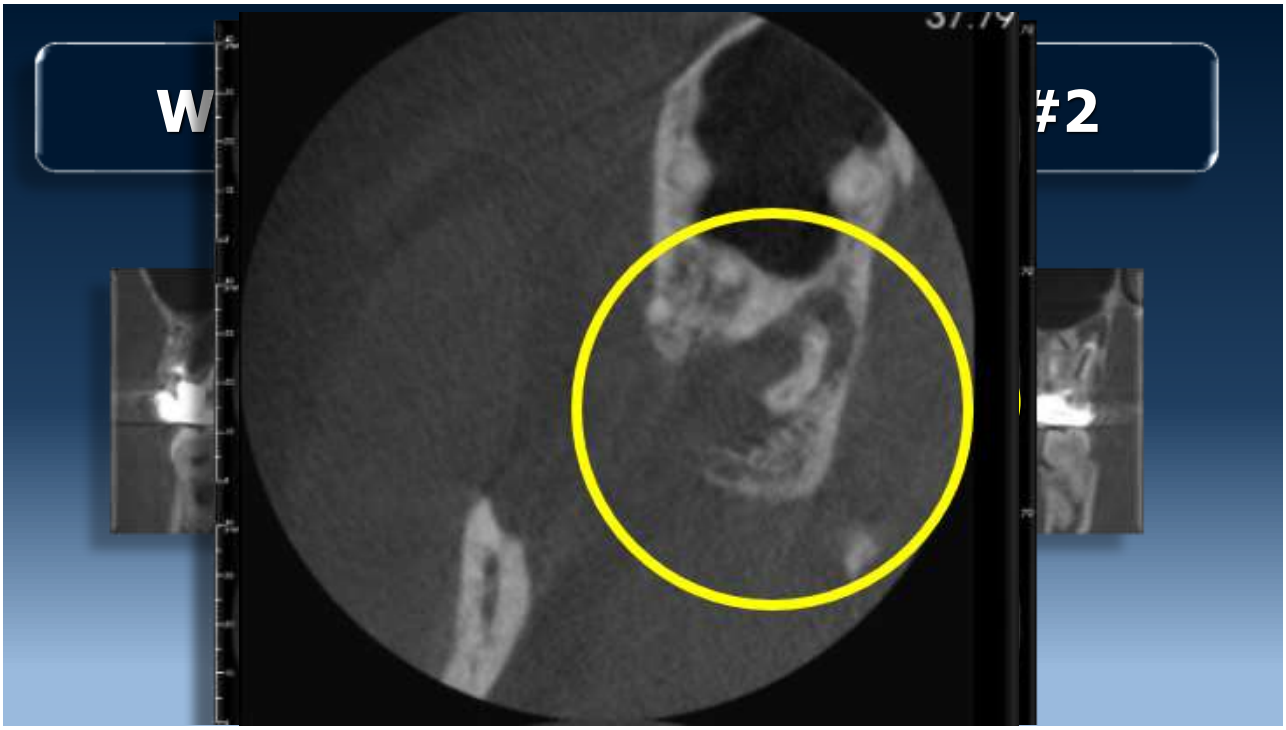
W
#2

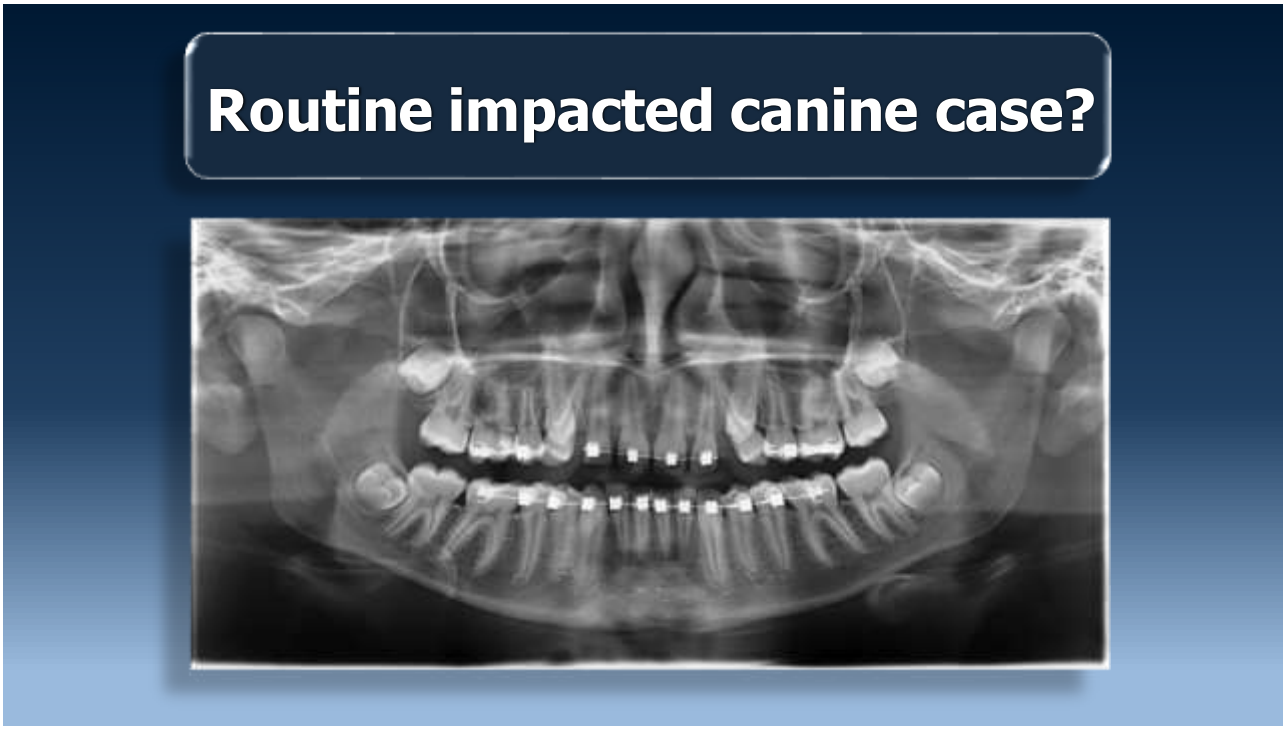
Routine impacted canine case?

The XG 3D revealed extensive bone loss around the upper right first molar

Drainage noted on lower right second molar but no radiolucency

CBCT revealed a large interradicular radiolucency

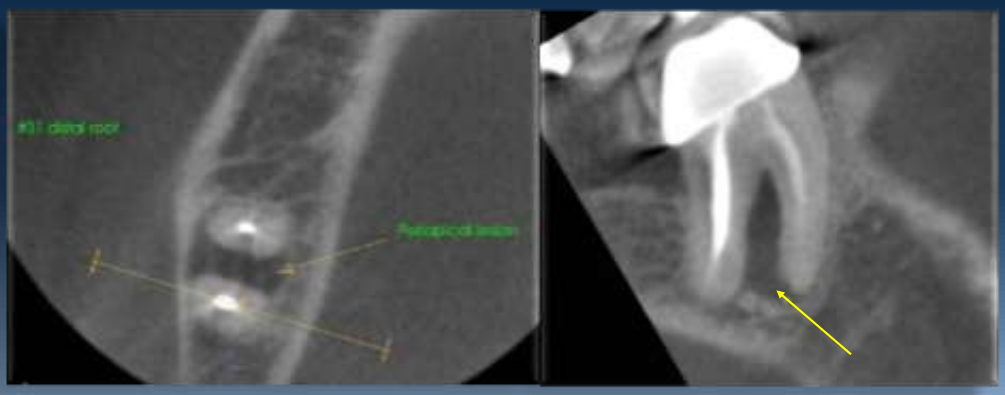

Periapical lesion "discovered" on #15 with CBCT but not noticed on the panoramic image

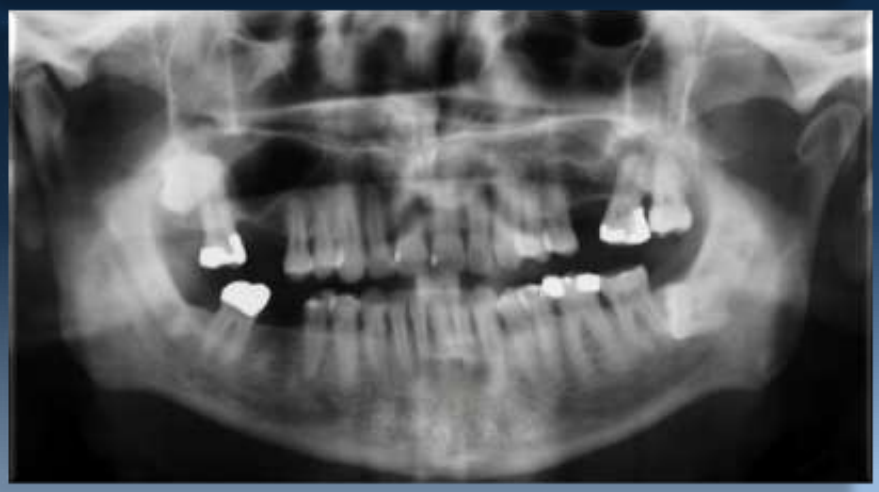

Pa lesion "discovered" on #15 with CBCT <u>not noticed on panoramic image</u>

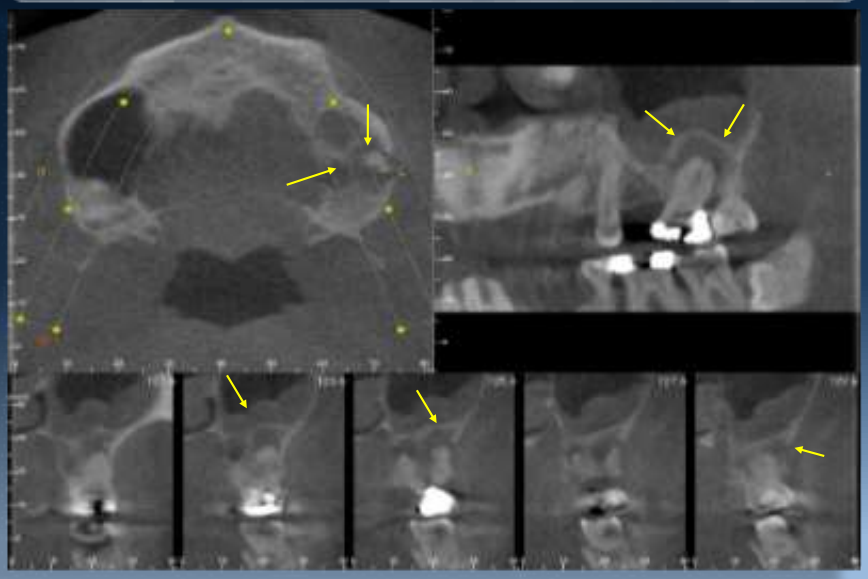

CBCT Evaluation of teeth not responding to endodontic therapy (missing MB 2 canal)

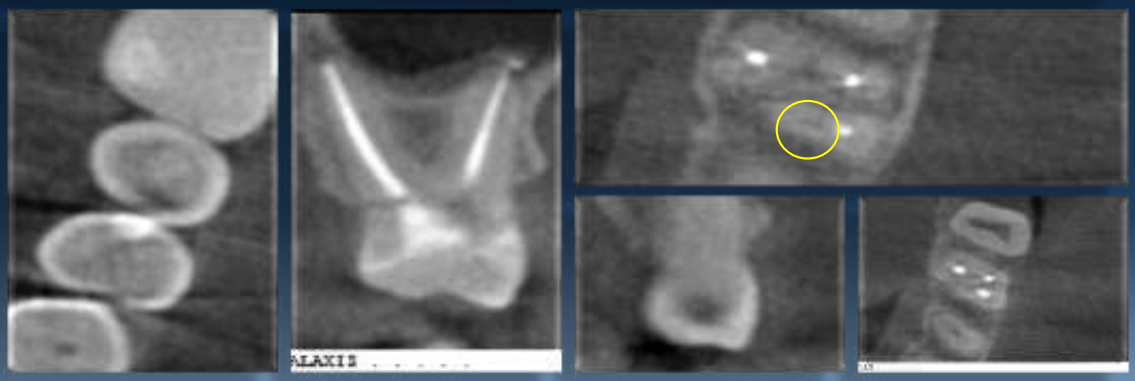

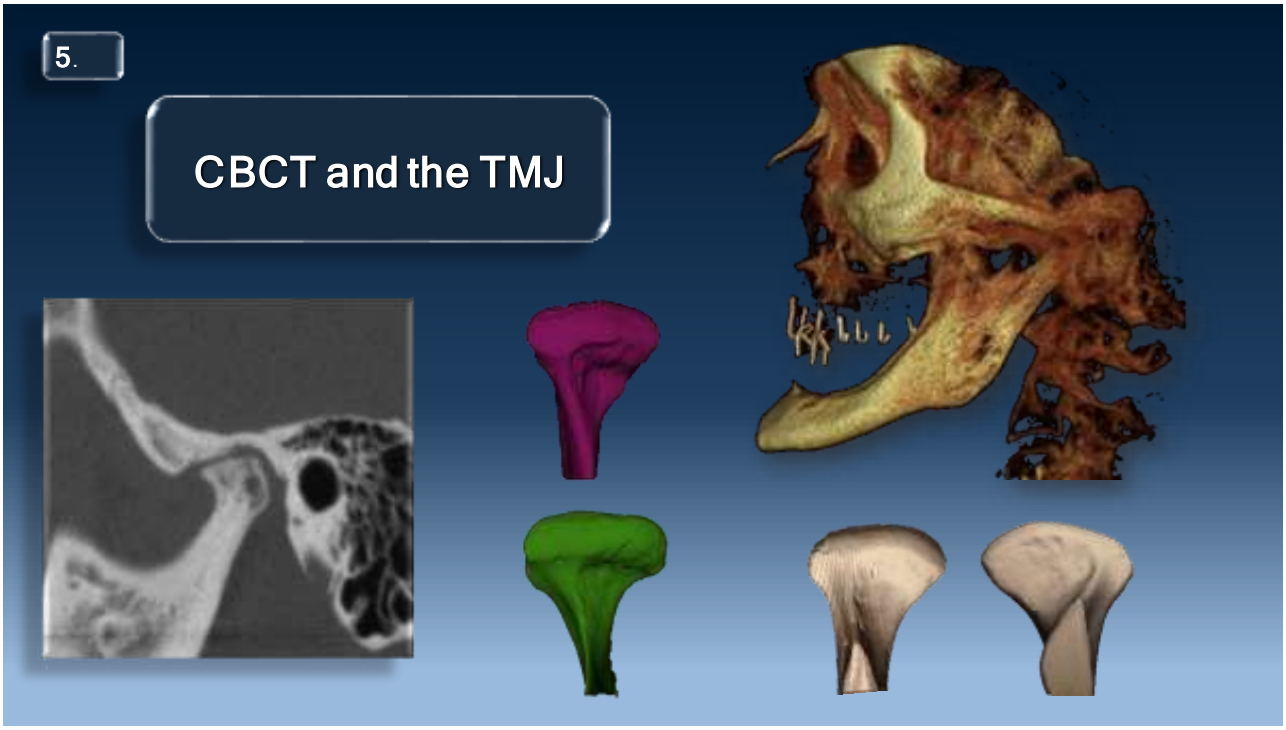
5.
CBCT and the TMJ

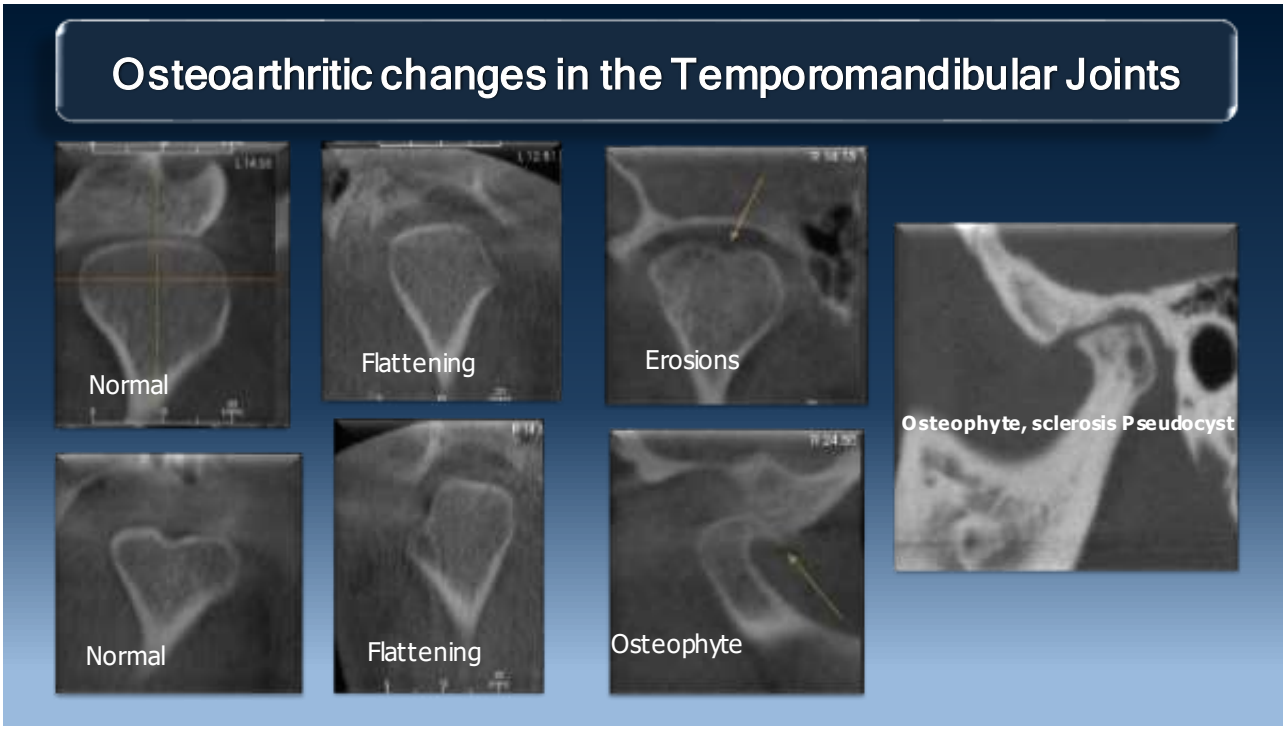
Osteoarthritic changes in the Temporomandibular Joints
Normal
Flattening
Erosions
Osteophyte, sclerosis Pseudocyst
Normal
Flattening
Osteophyte

Fracture through the glenoid fossa:
Not seen on the conventional panoramic images

4D Imaging

Pre and post treatment CBCT images can be superimposed and assessed with "mesh" visualization

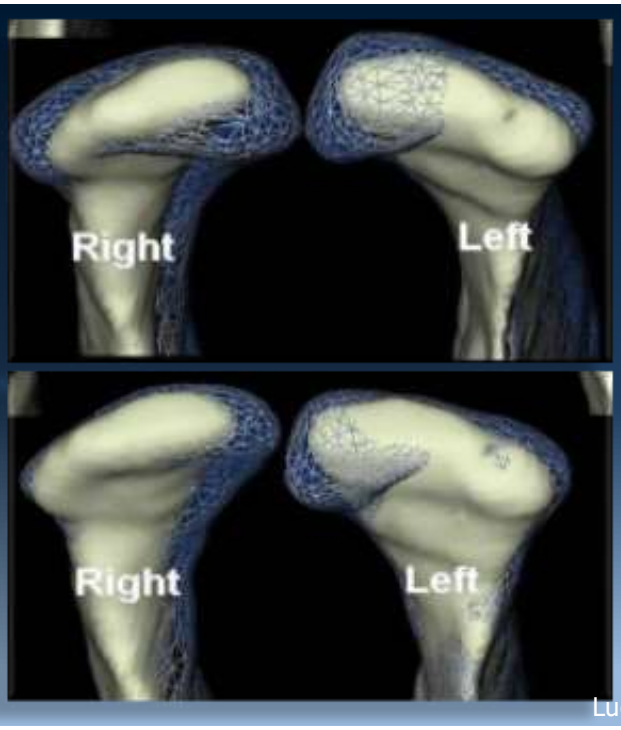

Lucia Cevidanes

6.

Trauma Applications

Extraction site (with pain) seen on a panoramic radiograph

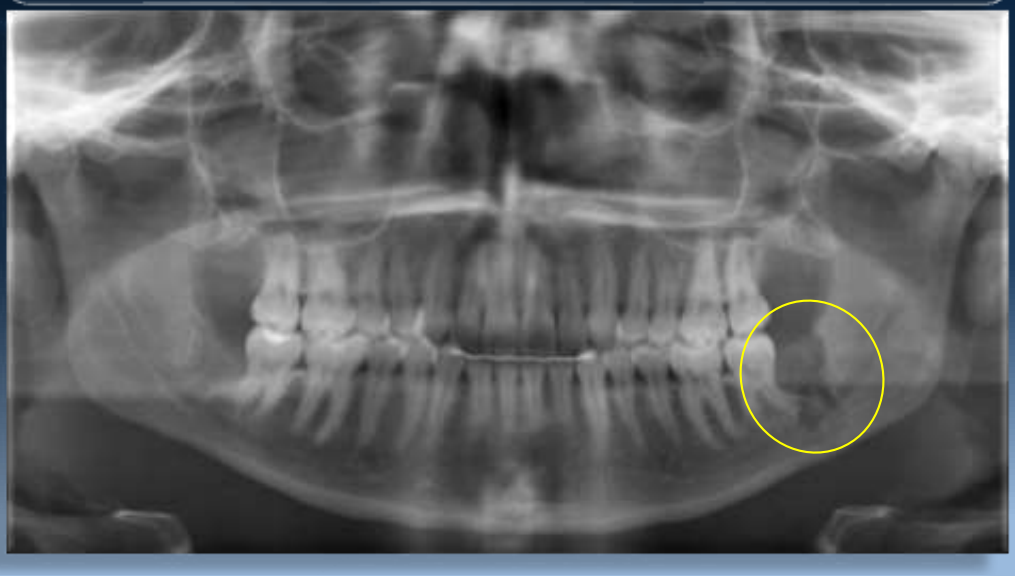

3D Cone beam CT Views

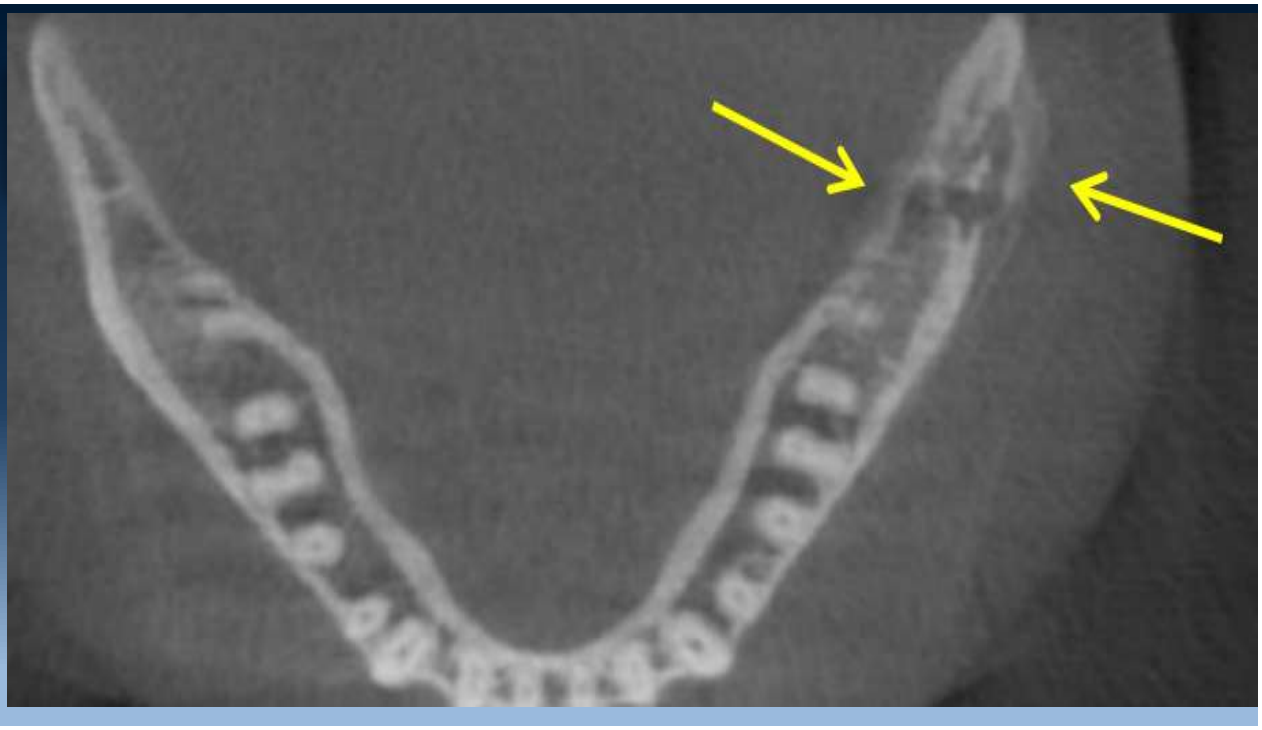

7.

Pathological Findings

Sinus Disease

- 50-year old female
- Pain in lower right thought to be associated with lower second molar
- Q: Where is the lesion?

Tangential and cross sectional views

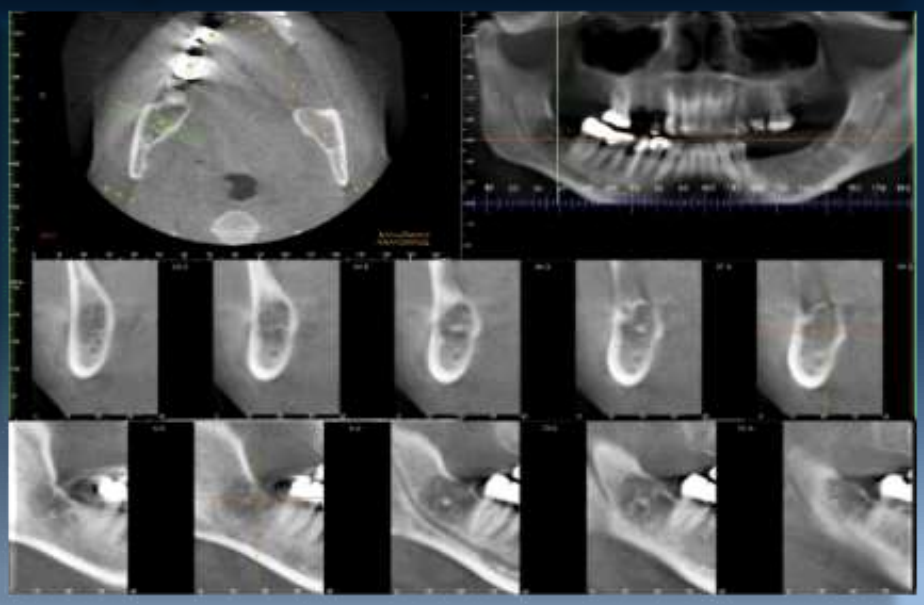

Recurrent Keratocystic Odontogenic Tumor in Left Maxilla…difficult to tell on panoramic radiograph

Confirmed Recurrent Keratocystic Odontogenic Tumor:
CBCT MPR views

- 12-year old female
- Slight swelling in the upper left: maxillary right premolars are displaced

Calcified Lymph Node: Deep cervical chain

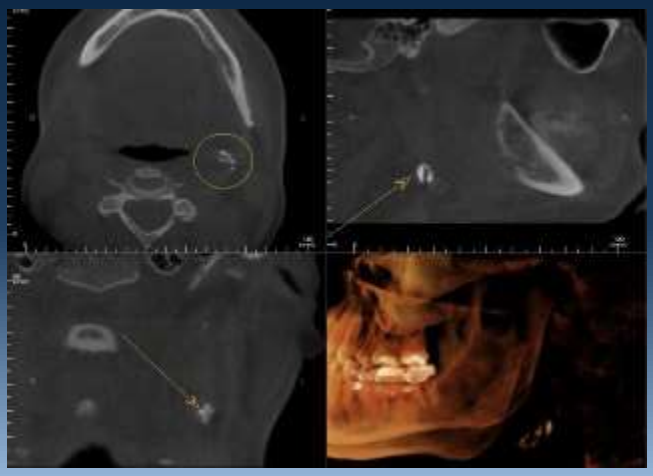

Calcified Carotid Atheroma: Common Location C-3 or C-4

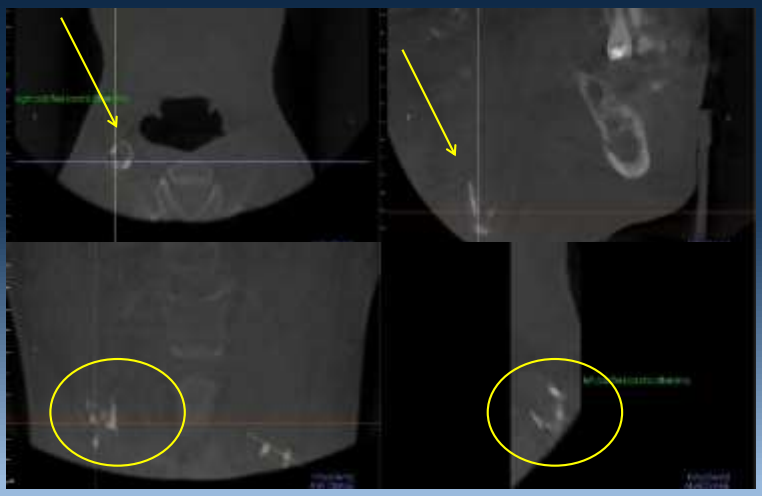

Bilateral calcified carotid atheromas

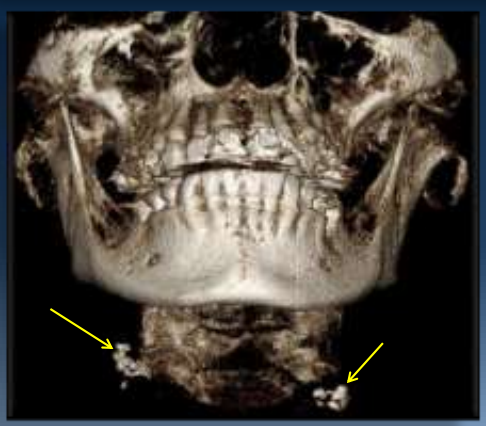

BRONJ (bisphosphonate-related osteonecrosis of the jaws)
CBCT and panoramic radiography

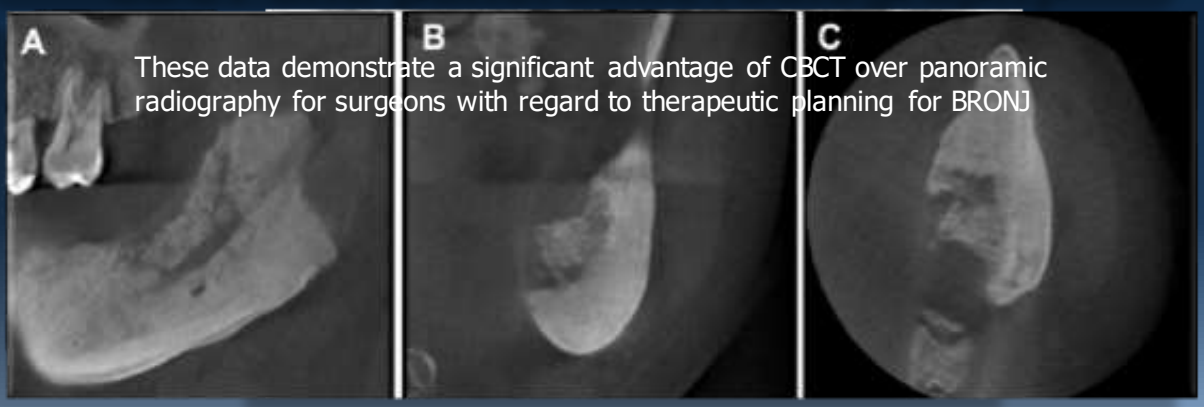

These data demonstrate a significant advantage of CBCT over panoramic radiography for surgeons with regard to therapeutic planning for BRONJ

Surgical evaluation of panoramic radiography and cone beam computed tomography for therapy planning of bisphosphonate-related osteonecrosis of the jaws
Oral Surg Oral Med Oral Pathol Oral Radiol 2016;121:419-424

Recurrent Keratocystic Odontogenic Tumor in Left Maxilla…difficult to tell on panoramic radiograph

Confirmed Recurrent Keratocystic Odontogenic Tumor:
CBCT MPR views

Unusual finding at an implant site

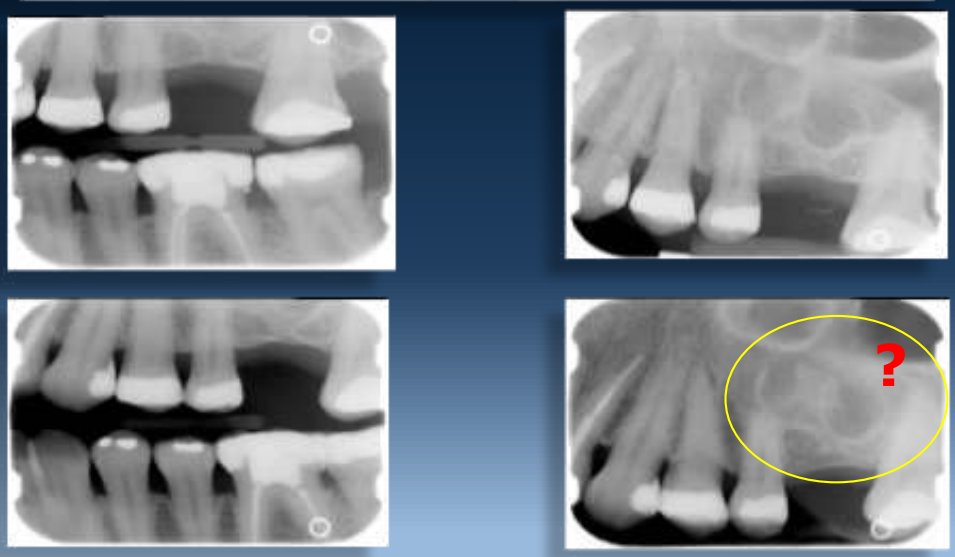

It turned out to be an oro-antral fistula from a previous extraction

Calcified Carotid Atheroma: Common Location C-3 or C-4

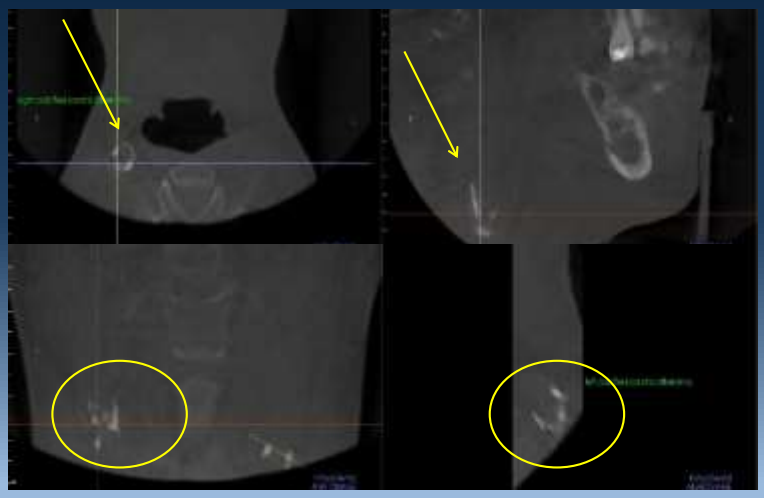

Bilateral calcified carotid atheromas

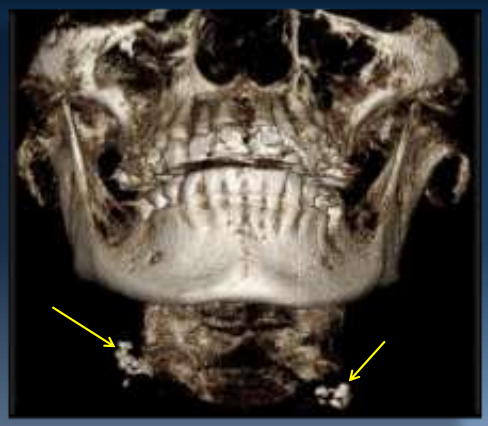

8.

Airway Assessment, Obstructive Sleep Apnea

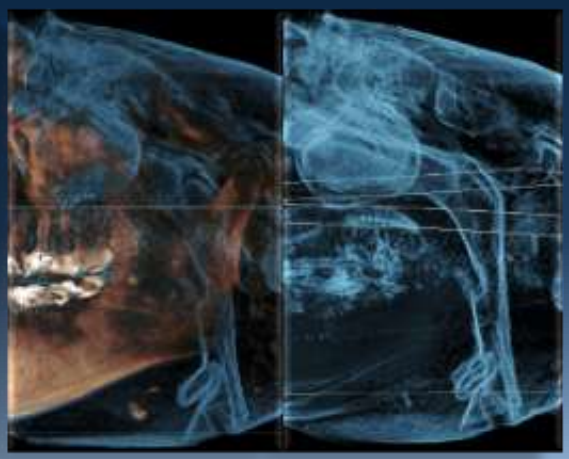

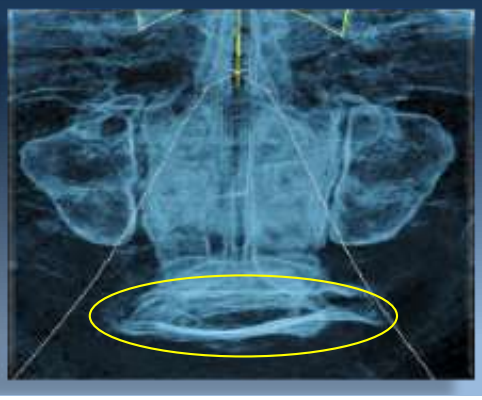

Sleep Apnea: Airway analysis using CBCT

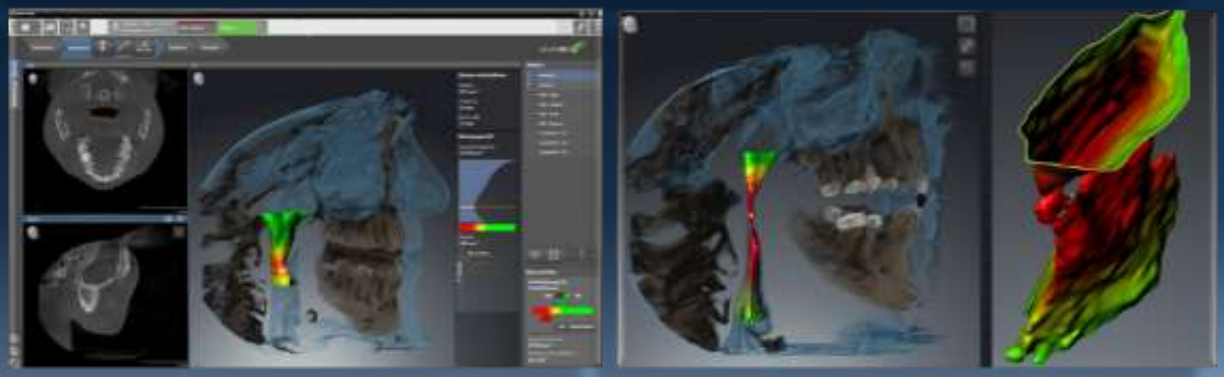

Using SiCAT Air

TMJ Function can be taken into account when designing the sleep apnea appliance

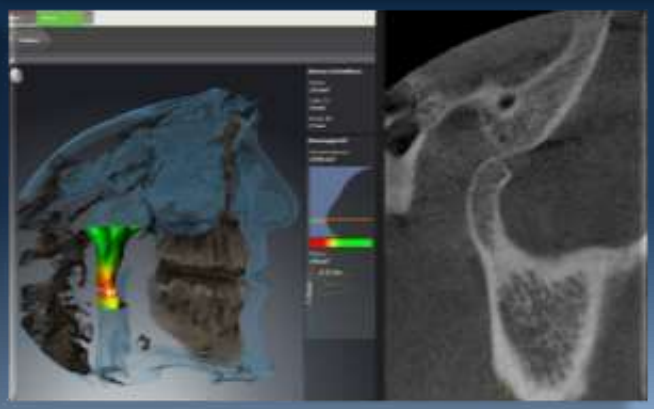

Two piece adjustable therapeutic appliance can be fabricated

Sleep appliance workflow

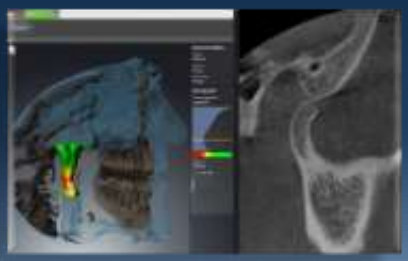

CBCT Scan

Airway and TMJ function analysis

Functional sleep appliance

9.

Orthodontic applications

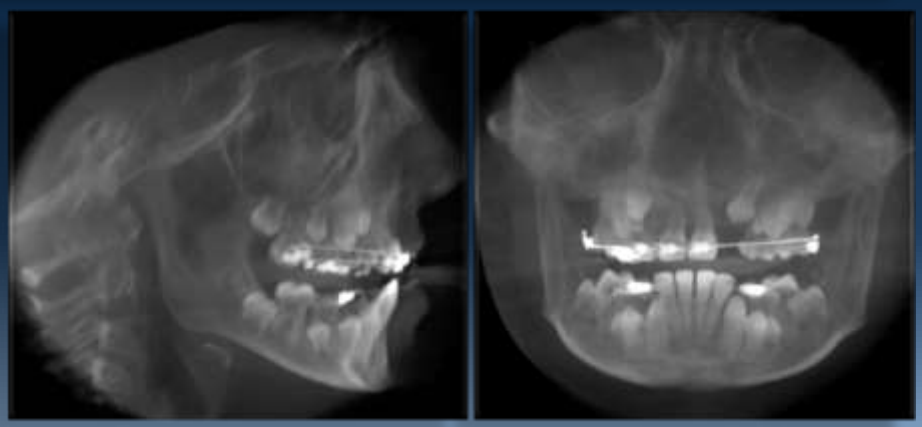

Creation of lateral and PA cephalometric radiographs from Galileos cone beam data

Impactions

- Location and orientation
- Morphology
- Relationships
  - Other teeth
  - Nasal fossa, maxillary sinus
- Path of alignment

Facially placed canine
Estimation of time to orthodontically correct was nine months

The panoramic image suggests that it may be possible to do so.

The CBCT volume suggests differently

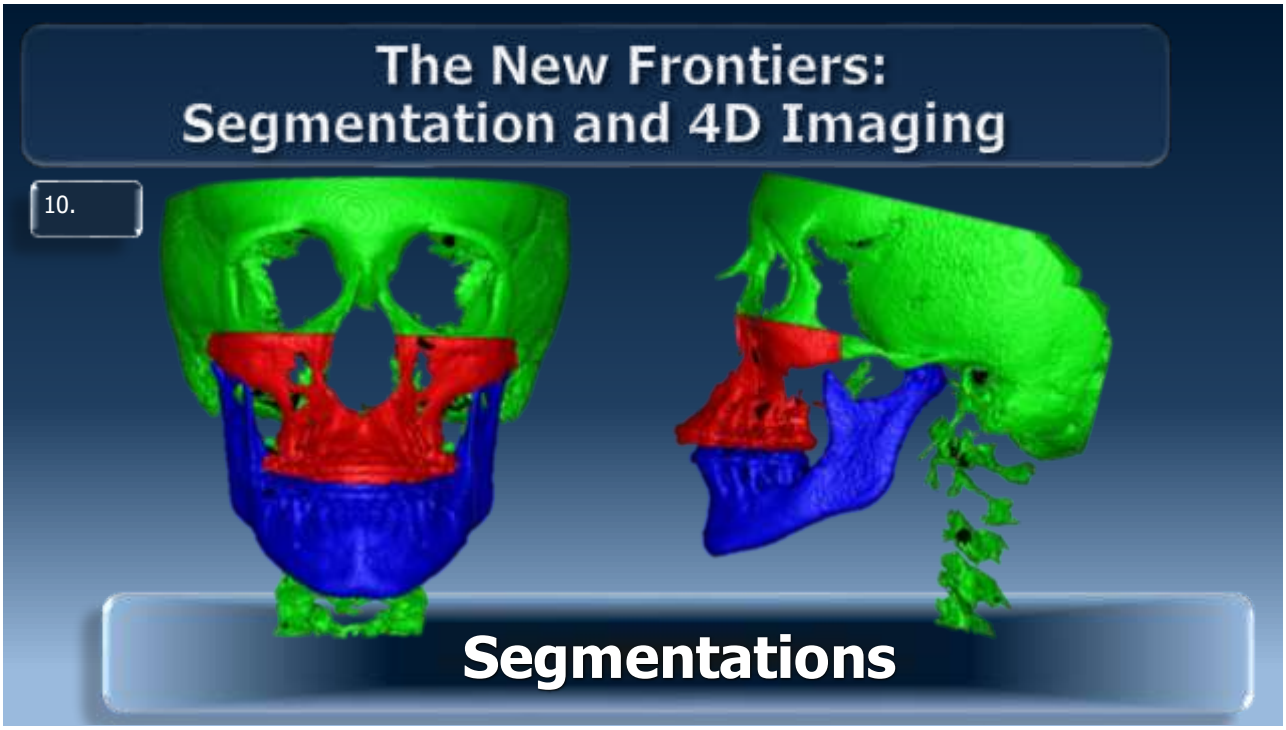
The New Frontiers:
Segmentation and 4D Imaging
10.
Segmentations

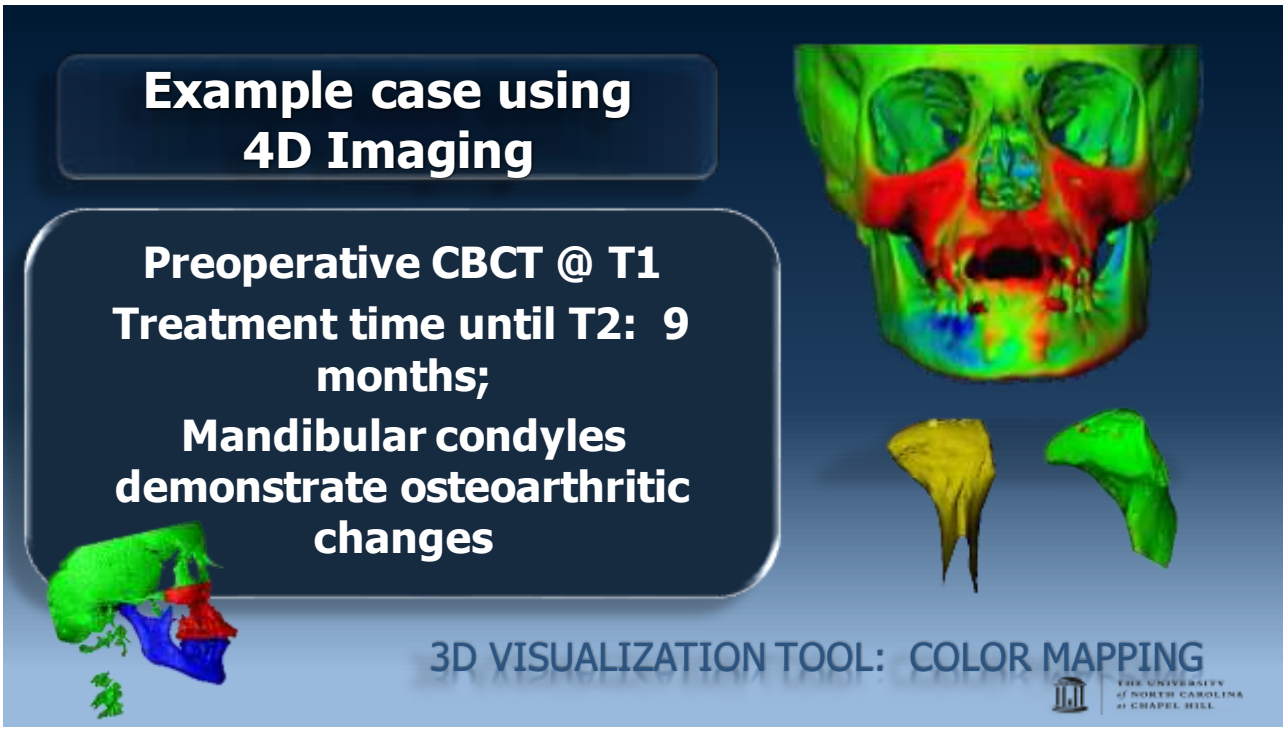
Example case using
4D Imaging
Preoperative CBCT @ T1
Treatment time until T2: 9 months;
Mandibular condyles demonstrate osteoarthritic changes
3D VISUALIZATION TOOL: COLOR MAPPING

The Future of Segmentation and 3D Printing

- Segmentation from a patient's CT scan could be used to print out a patient specific anatomical scaffold and then use stem cells to generate vasculature and bone (1,2).

Human TMJ engineered grown in vitro Gordana Vunjak-Novakovic, Ph.D

1. Temple JP, Hutton DL, Hung BP, Huri PY, Cook CA, Kondragunta R, Jia X, Grayson WL. 2014. Engineering anatomically shaped vascularized bone grafts with hASCs and 3D-printed PCL scaffolds. J Biomed Mater Res Part A 2014:102A:4317–4325

2. Cigan AD. Journal of biomechanics: Nutrient channels and stirring enhanced the composition and stiffness of large cartilage constructs. 12/18/2014;47(16):3847.

The Future of Segmentation and 3D Printing

"Andreas Herrmann of the University of Groningen in the Netherlands and his colleagues have developed an antimicrobial plastic, allowing them to 3D print teeth that also kill bacteria." NewScientist.com

Segmentation and subtraction for early detection of periodontal bone loss

2D does not show bone loss between #19, 18 3D shows the loss in red

Cone-Beam Computed Tomography Volume Registration for the Analysis of Periodontal Bone Changes

Green PT[1], Mol A[1], Tyndall D[1], Moretti A[2], Kohltfarber H[3]
[1]Department of Diagnostic Sciences and [2]Department of Periodontology, University of North Carolina at Chapel Hill School of Dentistry, Chapel Hill, NC
[3]Department of Radiology and Imaging Sciences, Loma Linda University School of Dentistry, Loma Linda, CA

CBCT and caries detection


RESEARCH ARTICLE

Ex vivo evaluation of new 2D and 3D dental radiographic technology for detecting caries

The XG3D showed significantly better cavitation detection sensitivity (0.62) than the other modalities (0.48–0.57).
…. The CBCT with artefact reduction demonstrated promising sensitivity/specificity for caries detection, somewhat improved depth accuracy and substantially improved cavitation detection.

What about dentoalveolar disease diagnosis?

- Caries?....conditional (still need intraoral)
  - Interproximal
  - Occlusal
  - Can detect cavitation better
- Periodontal bone architecture?...yes

CBCT was shown to provide financial cost benefits and time-savings for furcation-involved maxillary molars, especially for more complex treatments involving maxillary second molars. From Walter C, Schmidt JC, Dula K, Sculean A. Cone beam computed tomography (CBCT) for diagnosis and treatment planning in periodontology: A systematic review. Quintessence Int. 2016;47(1):25-37.

- Endodontic applications?...yes
  - Periapical lesions
  - Root fractures
  - Unfilled thin canals
  - Non-healing root canals treatment
- Panoramic replacement?..yes

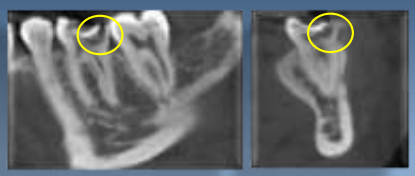

Future Developments in 3D Imaging

Future developments in CBCT
- Reduced costs and dose
- Customized fields of view
- More efficient flat panel detectors
- Automatic Exposure Control
- Improved software and software interfaces

Methods other than CBCT
- Tomosynthesis and carbon nanotube x-ray sources

Digital Tomosynthesis

Current research at the University of North Carolina School of Dentistry Radiology Group and the Department of Physics and Astronomy

- A Collaborative Effort Involving Faculty and Graduate students
- Dr. Otto Zhou: Department of Physics
- Dr. Andre Mol: Department of Diagnostic Sciences
- Dr. Enrique Platin: Department of Diagnostic Sciences
- Dr. Lars Gaalaas: Radiology Resident

Shan J, Tucker A, Gaalaas L, Wu G, Platin E, Mol A, Lu J, Zhou O. Stationary intra-oral digital tomosynthesis using a carbon nanotube X-ray source array. Dento maxillo facial radiology. Dentomaxillofac Radiol 2015; 44: 20150098

3D Intraoral Radiography: Tomosynthesis Theory

Dentomaxillofac Radiol (1997) 26: 53-62

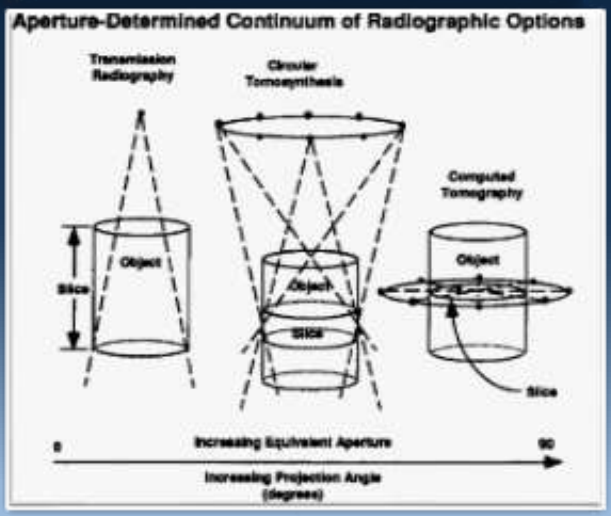

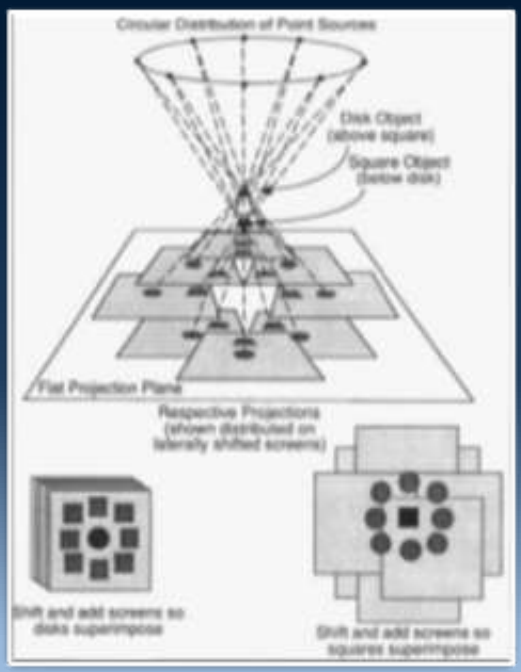

3D Intraoral Radiography

IMAGES – Tooth Anatomy

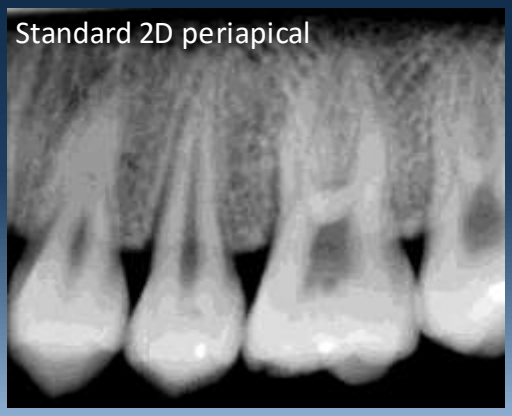

3D Intraoral Radiography

IMAGES – OPENING CONTACTS

3D Intraoral Radiography

Advanced reconstruction techniques maximize image quality with minimum dose

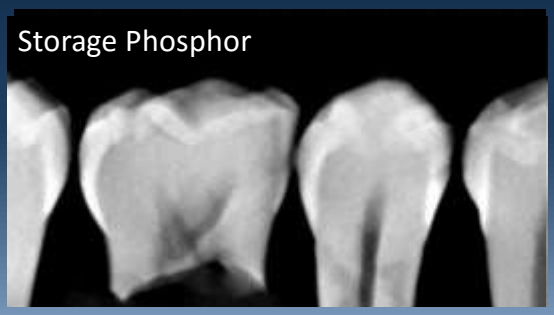

Today's Digital Dentistry is the …

In the future 3D won't be the diving board into dentistry

...it will be the pool

Remember: A sad tooth makes a sad patient and happy tooth makes a happy patient